



PL-BY-UA
2014-2020

GOOD PRACTICE CATALOGUE

This document has been produced with the financial assistance of the European Union, under the ENI CBC Programme Poland-Belarus-Ukraine 2014-2020. The contents of this document are the sole responsibility of dr Józef Psarski Mazovian Specialist Hospital in Ostrołęka and Communal Non-Commercial Enterprise of Lviv Regional Council Lviv Regional Children's Clinical Hospital "OHMATDYT" and under no circumstances can be regarded as reflecting the position of the European Union, the MA or the Joint Technical Secretariat of the ENI CBC Programme Poland-Belarus-Ukraine 2014-2020

This catalogue was created in cooperation of:

The Leader: dr Józef Psarski Mazovian Specialist Hospital in Ostrołęka

The Partner: Communal Non-Commercial Enterprise of Lviv Regional Council Lviv Regional Children's Clinical Hospital "OHMATDYT"

As part of the implementation of the project under the name *Join initiative of the Mazovian Specialist Hospital in Ostrołęka and Lviv Regional Children's Clinical Hospital »OHMATDYT«* as increase of accessibility of health care services in the scope of modern surgery as part of the Cross-border Cooperation Programme Poland-Belarus-Ukraine 2014-2020, Thematic Objective 3 Common challenges in the field of safety and security (SECURITY), Priority 3.1 1 Support to the development of health protection and social services

THE AIM OF THE PROJECT:

Improvement of availability of high quality medical services in the scope of modern surgery and increase of awareness of the society regarding impact of diet on human health.

Text authors:

Sabina Ponikowska, MD

Tomasz Szkółka MD, PhD

Seweryn Grzymała, MD

Fedir Yurochko, MD

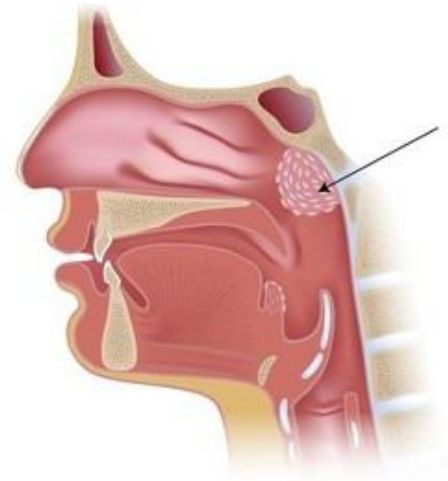
Andriy Dvorakevich, MD

Table of contents

| | |
|---|----|
| ADENOID DISEASES | 3 |
| RHINOSINUSITIS | 4 |
| ACUTE OTITIS MEDIA | 5 |
| HEARING LOSS..... | 6 |
| ACUTE APPENDICITIS IN CHILDREN..... | 7 |
| PALMARYHYPERHIDROSIS | 9 |
| CONGENITAL CONDITION. HOLLOWEDCHEST (PECTUSEXCAVATUM)..... | 10 |
| INGUINALHERNIAINCHILDREN..... | 12 |
| IMPORTANT ISSUES ABOUT THE BOYS (ADVICE FOR PARENTS). | 15 |
| LAPAROSCOPIC NEPHROUROLOGYIN CHILDREN. | 23 |
| CHOLELITHIASIS | 24 |
| ACUTE APPENDICITIS | 26 |
| PEPTIC ULCER PERFORATION..... | 28 |
| COLORECTAL CANCER..... | 31 |
| ENDOMETRIAL CANCER | 34 |
| OVARIAN CANCER | 38 |
| PROSTATIC CANCER..... | 43 |
| KIDNEY CANCER | 46 |
| References: | 49 |

ADENOID DISEASES

Adenoid diseases are quite common in childhood age. Most common are adenoiditis (adenoid inflammation), adenoid hypertrophy (growth) and tumors; fortunately, the latter ones are rare.



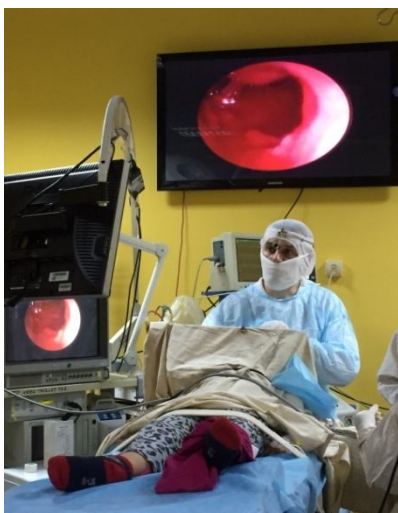Symptoms of adenoid diseases:

- Difficult nasal breathing
- snoring
- rhinolalia
- constant mouth breathing
- frequent long-lasting nose blockage
- sleep apnoe

If your child has these symptoms, you should consult an ENT doctor and have the child examined. Golden diagnostic standard of adenoid problem is flexible nasopharyngoscopy, which is successfully performed by the ENT doctors from the Department of Pediatric Otolaryngology of LRCCH “OHMATDYT”. Depending on the degree of the problem, adenoid diseases may require conservative or surgical treatment.

Indications for surgical treatment:

- chronic (more than 12 weeks) adenoiditis with rhinorrhea, despite at least 3-week antibiotic course
- chronic (more than 12 weeks) sinusitis, despite at least 3-week antibiotic course
- four or more episodes of recurrent adenoiditis with purulent otorrhea during past 12 months in children under 12 years
- chronic secretory otitis in children who are 4 years old or older
- adenoid hypertrophy, detected endoscopically/radiologically, with symptoms of respiratory tract obstruction (obstructive sleep apnoe)



Every day in the Department of Pediatric Otolaryngology of LRCCH “OHMATDYT” we perform various types of adenoid-related surgeries. The most frequently performed surgery is adenoidectomy. It is performed in two ways: classical and endoscopic one, developed and improved at our Otolaryngology Department. Quite frequently adenoidectomy is combined with other surgeries on the pharyngeal lymphoid tissue ring – reduction of palatine tonsils (tonsilotomy) and their removal (tonsillectomy) by means of traditional method or with the help of coblator (cold plasma surgery). Post-surgery period after such interventions

is relatively smooth, therefore our patients go home the next day after surgery.

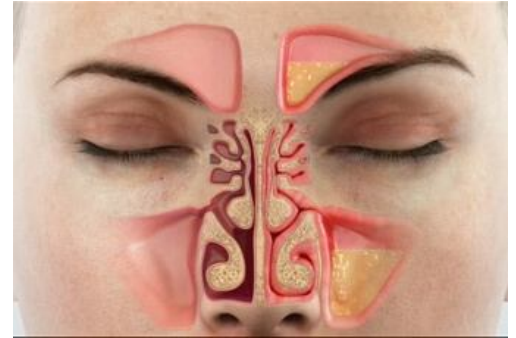RHINOSINUSITIS

Rhinosinusitis is inflammation of the nose and paranasal sinuses, characterized by two or more symptoms, one of which must be nasal blockage or nasal discharge, as well as cough, pain / facial pressure, decreased / lost sense of smell in combination with endoscopic manifestations or changes in computer tomography.

Prevalence of acute rhinosinusitis is very wide, thus it is difficult to estimate exact frequency of its occurrence. The incidence of acute viral rhinosinusitis (cold) is very high. It is described that adults and children over 16 have from 2 to 5 episodes of viral rhinosinusitis per year, while school-age children have up to 10 episodes per year. The share of acute postviral rhinosinusitis is from 17 to 21%. Approximately 0.5-2% of viral upper respiratory tract infections are complicated by bacterial infection.

Rhinosinusitis symptoms:

- nose blockage
- nasal discharge
- cough
- decreased/lost sense of smell
- headache/facial pressure
- fever, weakness, loss of appetite

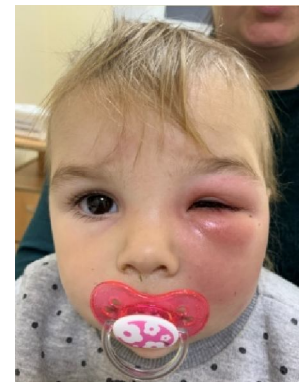

If your child has these symptoms, he/she needs ENT examination. Rhinosinusitis is a clinical diagnosis, but in some cases complete examination of the child requires a CT scan of the nasal sinuses.

There are a number of symptoms and signs that indicate a complicated course of acute rhinosinusitis and are an indication for immediate hospitalization of the patient in a specialized pediatric otorhinolaryngology department.

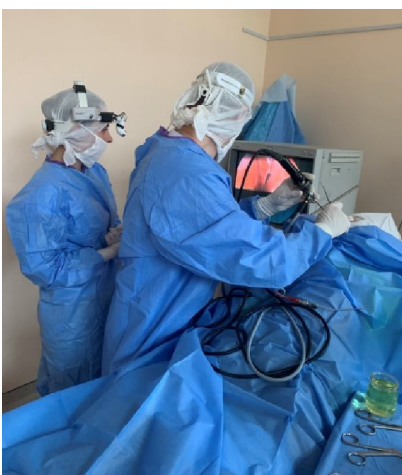Signs of rhinosinusitis complications:

- eye reddening and edema
- ocular displacement
- diplopia
- abrupt impairment of visual acuity
- edema in frontal area
- strong pain in frontal area
- signs of meningitis, sepsis



In most cases treatment of rhinosinusitis is conservative, however, when rhinosinusitis is complicated, surgical intervention is necessary. The main surgical intervention in complicated acute or chronic rhinosinusitis,

which is performed on the basis of the Department of Pediatric Otorhinolaryngology of the Lviv Regional Children's Clinical Hospital "OHMATDYT" is functional endoscopic surgery of paranasal sinuses (FESS – functional endoscopic sinus surgery).



ACUTE OTITIS MEDIA

Acute otitis media (AOM) or otitis media is one of the most common childhood diseases in the world. Approximately 75% of children have experienced at least one episode of ear infection before school age. Of these children, most children have AOM before they become 2 years of age. The peak incidence is the age from 6 to 18 months. This pathology is the first reason to consult a pediatric otolaryngologist, as well as the most common indication for prescribing antibiotics.

Symptoms of acute otitis media:

- earache
- acute onset
- otorrhea
- hearing loss
- fever
- breast feeding rejection, restlessness, ear rubbing – in infants




If all of a sudden your baby has these symptoms – immediately consult an otolaryngologist. An ear examination is mandatory to confirm this diagnosis, as there are a number of other diseases that can be masked by acute otitis media. Such examination will determine further treatment of your child. Treatment of acute otitis media can only be conservative (local and systemic anesthesia, antibiotic therapy), and can be combined with surgery.

Ear surgeries performed in the Department of Pediatric Otolaryngology of the LRCCCL "OHMATDIT" are very diverse. Myringotomy is quite common: this is an incision of the eardrum to evacuate pus, which is present in the case of severe acute otitis media. Tympanic membrane shunting surgery is an operation indicated for recurrent acute otitis media, when their frequency is 3 episodes in six months or 4 in a year.

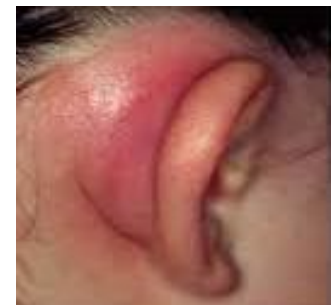Myringoplasty is the correction of tympanic membrane defects caused by frequent ear problems performed to improve the child's hearing.

It is worth noting that acute otitis media is dangerous because of their complications.



Signs of complicated acute otitis media:

- bulging external ear
- reddening and edema behind the ear
- dizziness
- nausea



The most common otogenic complication is mastoiditis. The Department of Pediatric Otolaryngology of the LRCCCL "OHMATDIT" is the only department in the region dealing with such problems in children. Fundamental mastoiditis treatment is surgery - open/closed antromastoidotomy together with tympanostomy, the combination of which reduces risks for lives of our patients.

HEARING LOSS

There are many different causes for hearing loss in children. In some cases, sudden hearing loss may require immediate medical attention of an ENT doctor. Understanding the possible causes, targeted examination and immediate treatment or counseling increases the patient's chances for 100% recovery of hearing.

If you have some doubts about your child's hearing, answer the following questions:

1. Does the speech of the child correspond to his/her age?
2. Does the child always understand your speech correctly?
3. How often does the child ask you to repeat?
4. How often does your child have ear infections?




| Causes of sensorineural hearing loss | |
|--------------------------------------|--|
| Infection | Viral and bacterial infections |
| Vascular | Thromboembolism |
| Injury | Fractures of temporal bones |
| Neoplastic process | Primary and metastatic |
| Iatrogenic | Induced by medications, radiotherapy or chemotherapy |

| Causes of conductive hearing loss |
|-----------------------------------|
| Cerumen impaction |
| Foreign body |
| External otitis |
| Secretory otitis |
| Cholesteatoma |
| Middle ear tumours |
| Otosclerosis |

Treatment efficiency of such patients depends on the primary examination. Hearing problems can develop in one or two ears, can be congenital or acquired. Apart from otoscopic picture diagnosis in such cases is based on audiometry, tympanometry and CT of temporal bones.

Treatment of hearing loss of different origin can be both conservative and surgical. In some cases such children need cochlear implants or hearing aids. In the Department of Pediatric Otolaryngology of the LRCCH "OHMATDYT" the doctors also perform a number of ear surgeries to improve hearing of our patients. Among them are: shunting of the tympanic membrane, myringoplasty and removal of ear neoplasms (cholesteatoma, etc.).



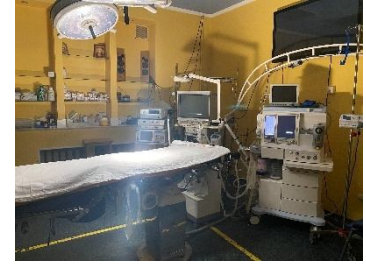

ACUTE APPENDICITIS IN CHILDREN

May appear at any age and is more difficult to diagnose in kids than in adults as appendix inflammatory process in children develops much faster and is more frequently complicated with peritonitis.

Acute appendicitis potential causes:

- Appendix anomalia – flexure, atypical location;
- Foreign body in the intestinal tract, fecaloma, parasites;
- Other inflammatory processes of intestines.

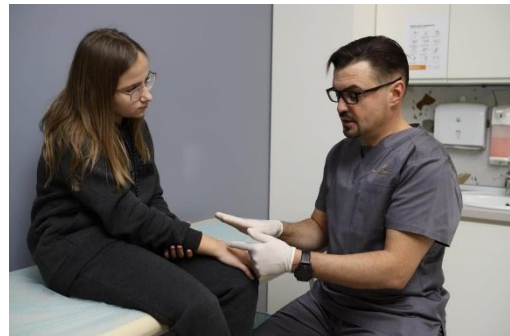

The first symptoms of acute appendicitis in children is pain around the navel, restlessness, nausea, loss of appetite and fever, impaired bowel function that can manifest themselves already 12 hours after the onset of the disease. With inflammation progress the pain moves to the right low quadrant of the stomach or become extended, with muscular defence and peritoneal irritation symptoms.

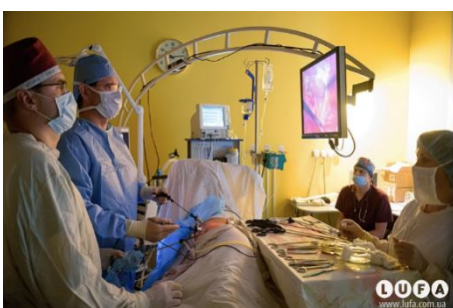
Appendicitis symptoms may look different, depending on its location and the clinical form.

- In retrocecal or retroperitoneal location, the pain may be mainly felt in the lateral abdomen or back, without clear local symptoms in the right iliac region.
- In the subhepatic location, the pain may be in the right hypochondrium, or in the right iliac region with irradiation of pain in the back or hypochondrium.
- In the pelvic position, when appendix is adjacent to the ureter or bladder, when the pain radiates to the groin area, there is frequent urination and dysuric phenomena.
- Within complete intestine rotation appendix is located in the left abdominal quadrant.
-

Apart from lab tests such diagnostic methods as ultrasound, abdominal cavity or appendix X-ray or CT are diagnostically informative. Currently the ultrasound diagnostics of the acute appendicitis is very helpful, especially with its abnormal location and presence of infiltrate, abscess, thickening of its wall, foreign body detection, presence of free liquid in the abdominal cavity and exclusion of other pathologies.



In our Lviv Regional Children's Clinical Hospital "OHMATDYT" (hereinafter LRCCH "OHMATDYT") acute appendicitis and its complications are treated with both open, and laparoscopic method. Recent years show prevalence of minimally invasive method of appendectomy.



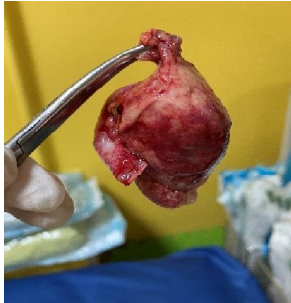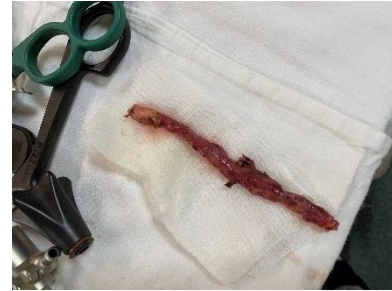Laparoscopic appendectomy is performed through 3 small punctures 3, 5 and 10 mm long, one of which is located in the umbilicus, in mesogastrium parallel to the umbilicus to the left and in the left iliac area. Video camera and special tools with which the surgeries are performed are

inserted through these punctures.

Advantages:

- Clear cosmetic benefits, such punctures are almost invisible.
- Rehabilitation time and return to physical activities is shorter than with open surgery.
- Significant benefits with atypical location of the appendix. In open surgery the incision is several centimeters larger, which is not the case with laparoscopy.
- Reduce the risk of infection introduction and other complications – adhesions, hernias.
- Less traumatic for overweight and obese patients.
- Better hemostasis management
- Less traumatic for muscular and cutaneous tissues.

Additional advantage of laparoscopic access is the possibility to examine the whole abdominal cavity, uterus and its appendages. In case there is gynecological pathology, it is possible to immediately correct it using the same ports, and if the appendix is unchanged, it is not removed.



Thus, in case that raises some doubts we can do diagnostic laparoscopy for differential diagnostics of other acute surgical pathologies of both abdominal cavity and pelvic organs.

After detection, appendix is removed from the surrounding tissues and separated from the cecum and mesoappendix. Sometimes appendix removal requires application of the retrograde laparoscopic appendectomy technique. In this case first of all the head of the appendix is removed, it is separated from the cecum and ligature is applied and only later it is separated from the mesoappendix.

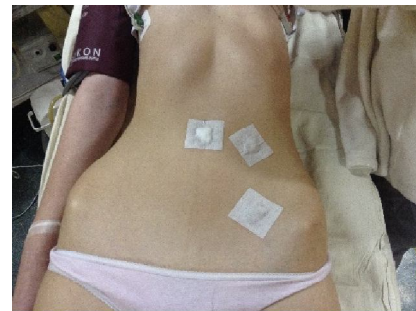During appendicitis surgery, surgery time depends on the location of the appendix and other aspects.

On average, it lasts from 30 minutes up to 1,5 hours.

Post-surgery period:

As a rule, rehabilitation after non-complicated appendicitis in the hospital takes 1-2 days.

Complicated with peritonitis – up to 7 days.



Prevention of appendicitis and its complications :

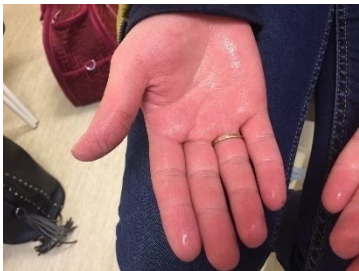1. Proper nutrition of children and adolescents - avoiding overeating, limited consumption of fried, smoked foods and fast food. Fiber- and vitamin-rich diet following age-related requirements and frequency of food consumption.
2. Prevention of chronic constipation.
3. Prevention of helminthic infection.
4. No self-treatment – uncontrolled usage of antibiotics, analgetics, methods of non-protocol medicine («hot water bag on the stomach», warm water enema, etc.)
5. Timely consultations of a doctor – prevention of various complications of acute appendicitis, namely:
 - general peritonitis;
 - post-surgery adhesive processes causing acute and chronic bowel obstruction (disability of the patient);

- infertility in future;
- significant increase in the cost of complicated appendicitis treatment.



PALMARYHYPERRHIDROSIS

Hyperhidrosis is the condition characterized by abnormally excessive sweating exceeding one necessary to regulate body temperature. Hyperhidrosis can be related to worsening of life standards from psychological, emotional and social point of view.



Hyperhidrosis can be classified into:

- Primary (idiopathic);
- Secondary –after a certain disease (hyperthyreosis, diabetes mellitus).



Depending on the prevalence:

- Local (palmary, axillary);
- Widespread.

Depending on the course of the disease:

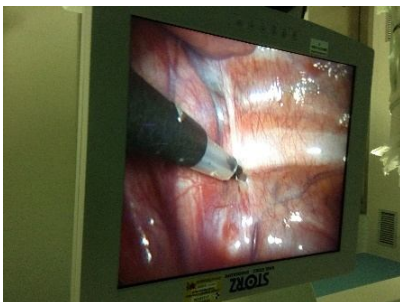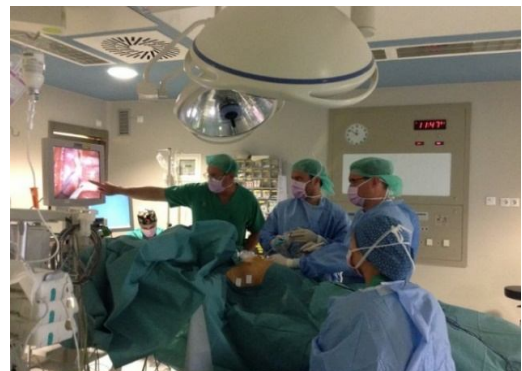- Compensatory (after sympathectomy surgery in case of palmary hyperhidrosis);
- Emotional or caused by physical factor;
- Nocturnal (during sleep).

Our experience of treating such patients:

Such surgeries have been conducted since 2015 among the patients who had surgery there are 34 boys/men and 45 girls/women from 8 to 47 years old.

Conservative methods (botox injection, local treatment, aluminum-high antiperspirant) give temporary result.

In LRCCH “OHMATDYT” we perform bilateral selective thorascopic sympathectomy. Such surgical intervention is performed on both sides of the chest along the midaxillary line with 3 or 5 mm incisions, inserting 2/3 of portacath.



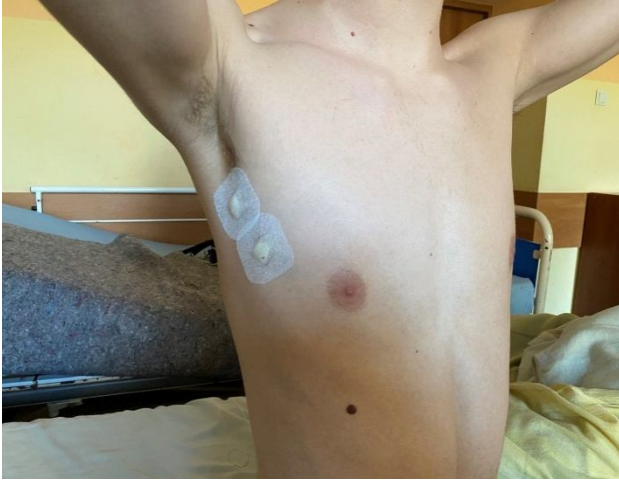Phased electrical destruction of nerve fibers is conducted with ultrasonic scalpel along the inferior rib edge with aspiration of air from pleural cavity.

We measure palm temperature before and after surgery:

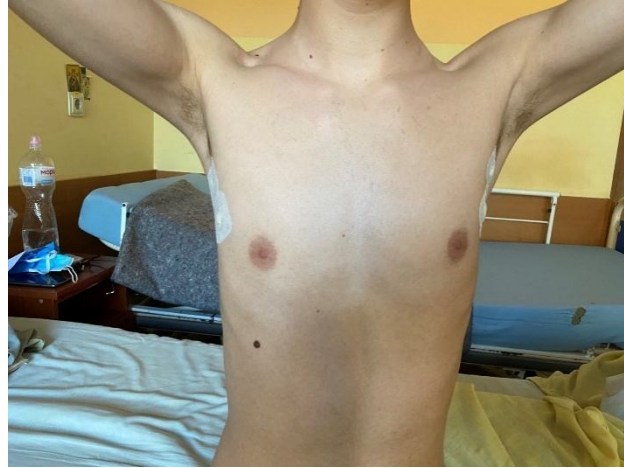

Before

Palms become dry and warm immediately after the surgery and continuously remain in such condition. Inpost surgery period sometimes one can observe residual pneumothorax and development of compensatory hyperhidrosis - (back, back part of the thigh) which is well tolerated, considered socially more tolerable than palmary hyperhidrosis.



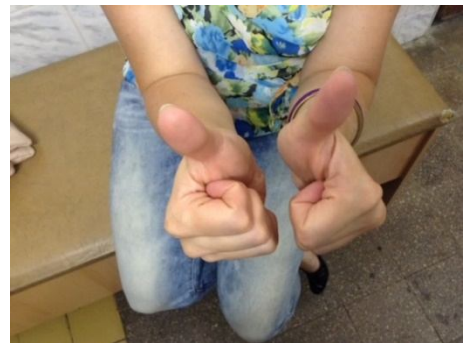After



Профілактика гіпергідрозу:

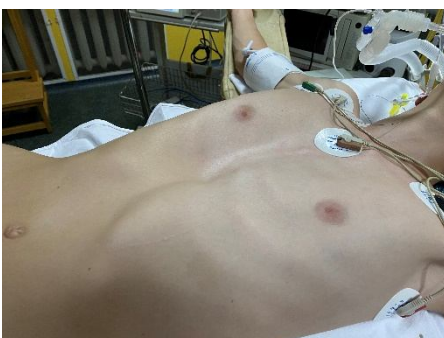
Asthis disease is characterized by congenital nature and often involves hereditary aspect, disease prevention measures are the following:

1. Wearing clothes from natural fabric and leather shoes.
2. Avoiding medications whose side effects may enhance hyperhidrosis.
3. Stress reduction and doing autotraining.
4. Promoting knowledge about idiopathic hyperhidrosis of palms and feet that will result in decreased number of unnecessary and sometimes even harmful recommendations and consultations of a neurologist/psychoneurologist.



CONGENITAL CONDITION. HOLLOWED CHEST (PECTUS EXCAVATUM).

The most common type of chest deformation that manifests itself when the child is born and more often happens in boys.



Among the causes are congenital deficiencies of rib cartilages, syndrome of undifferentiated connective tissue dysplasia, with breast bone and lower rib cartilages bent to the spine. Also the reigenetic factor, presence of concomitant scoliosis or Marfan syndrome, cardiac valve pathology.

When the child grows, deformation increases and children may have physical developmental delay.

There are following deformation degrees:

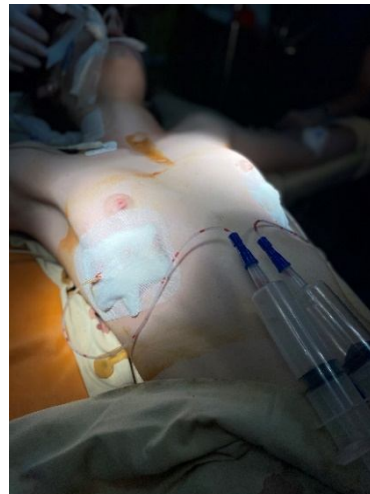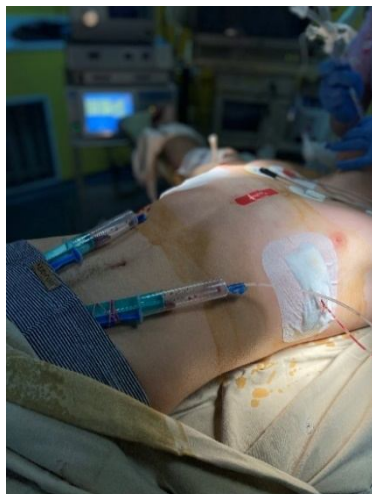1st degree – deformation depth is up to 2 cm, without heart displacement.

2nd degree – deformation depth is up to 4cm, with heart displacement up to 3 cm to the left.

With 3rd-4th degree of deformation the can be changes in cardio-vascular and respiratory system because the hollowed breast bone which presses on the heart and great vessels, dislocating them to the left.

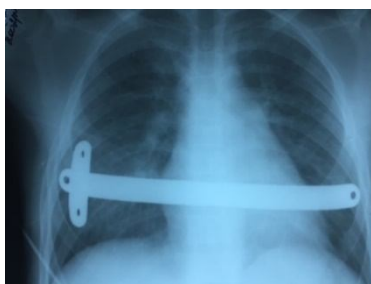
Deformation of the 1st degree can be corrected in a non-surgical way with the help of special gymnastics or certain kinds of sport. Other deformation degrees are corrected with surgical methods.

Optimal age for surgical treatment is 12-16 years.



Since 2005 LRCCH “OHMATDYT has been correcting this pathology with the help of metalsternal chondrodistraktion by Nuss-Park technique with videothoroscopic control, when post-thoracic tunnel is created for metal element insertion and fixation (one or two plates, with or without fixator).

Our surgical team slightly modified this surgery, making this intervention easier and ensuring better post-surgical rehabilitation.



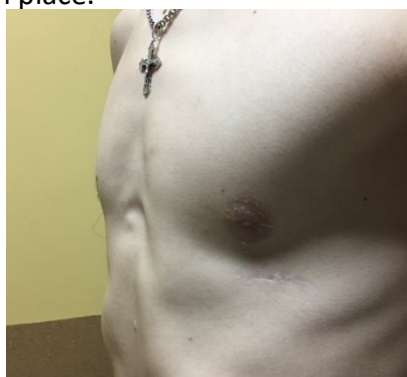
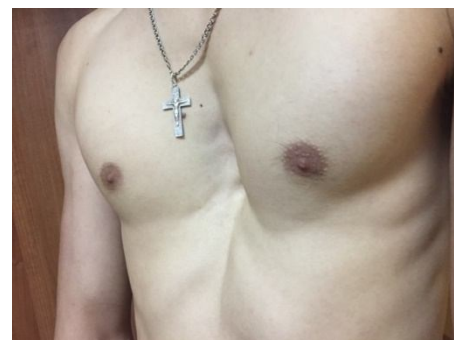Post-surgical X-ray of the patient – plate is in the area where breastbone is sunken the most and there is an additional fixator on the left.

Post-surgery anesthesia is administered by means of elastomer pump, anesthetic administration rate can be regulated by the patient depending on the pain syndrome.

In 2-3 years the second surgery stage is conducted

– the plate is removed.

After plate removal the correction achieved is in place.



During the second surgery incisions are made in the same place on top of the old cicatrices, thus, there are no new scars.

Prevention of the hollowed chest (chest deformation in general):

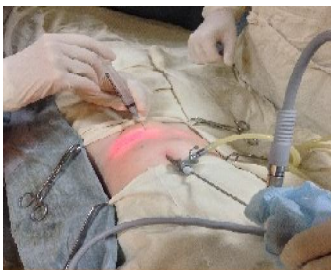1. Timely seeking medical advice (consultation of a professional doctor specializing in this condition).
2. Doing physical exercises, going in for sport (swimming, water polo, rowing, skiing, pilates).
3. Recommendations to take up music classes (playing wind instruments – flute, saxophone, reed pipe, trumpet).



INGUINAL HERNIA IN CHILDREN

Inguinal hernia in children is one of the most common pathologies encountered by children's surgeons both during scheduled and urgent surgery.

It is more common in boys than in girls (10 times more frequent) which is related to testes descent through the inguinal canal.



Inguinal hernia in children's surgery in the majority of cases is congenital developmental issue when abdominal organs – bowel in boys, in girls also ovary, penetrate through the patent open peritoneal diverticulum that leads to the trauma of the organs, and when pressed – to the organ necrosis.

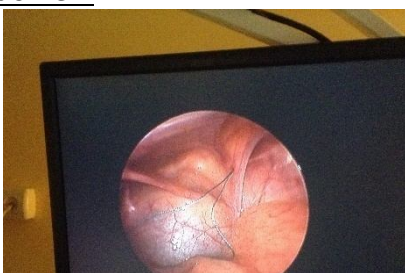
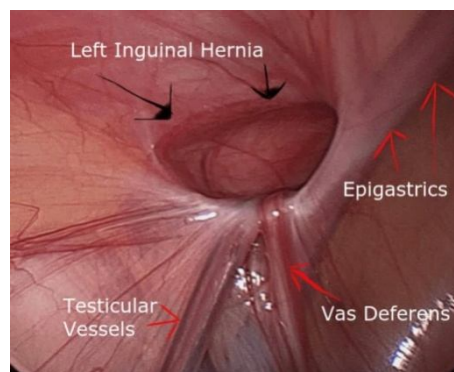
Hernia can be acquired due to weakness, under development of muscles and connective tissue of the abdominal wall, when hernia protrusion goes through the inguinal fossa. Such hernias mainly occur in teenage years due to physical activity.

One can suspect inguinal hernia on the basis of anamnesis data and objective examination, such as:

- soft round mass in the groin, scrotum and in the area of outer labia, which usually does not cause any pain but causes discomfort;
- protrusion becomes noticeable or grows in size, when the child is strained: crying or coughing (cough impulse);
- in lying position or when the child is relaxed, the mass decreases in size or disappears.

When inguinal hernia is not complicated, the bowel may freely move outward or inward through the enlarged inguinal ring.

Strangulated hernia is a dangerous condition, when it is impossible to reduce organs back into the abdomen.



Clinical manifestations of strangulated hernia:

- sharp abdominal pain, no passage of flatus;

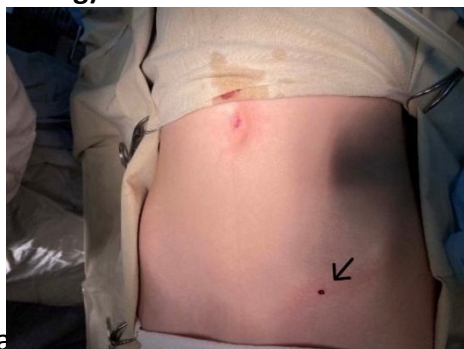
- hernia protrusion becomes tense, painful, with hyperemic skin, hernia cannot be reduced into the abdomen;
- general condition of the child is impaired, the child is restless, there may be nausea, bloating, fever.

Surgical treatment

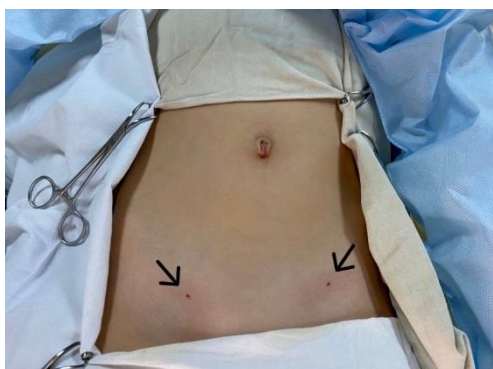Optimal time for surgery is from three months up to 5 years of age, if hernia is not strangulated. In other cases it is urgent surgical treatment.

In our hospital we apply low invasive method of surgical treatment of this pathology – **laparoscopic hernioplasty based on P.I.R.S. (Percutaneous Internal Ring Suturing).**

Laparoscopic intervention is performed not by means of inguinal canal incision, but by applying percutaneous internal ring suturing through one 3-5 mm puncture above the ring and inserting optical tool through the umbilicus, such a puncture is sutured with internal suture and is almost invisible.



The advantage of this surgical intervention is that we can expand it, it is possible to perform simultaneous correction on both sides.



After such surgery the pain syndrome is significantly low, aesthetically the area looks better and in the evening the child may leave the hospital.

Prevention of inguinal hernia and its complications:

1. Inguinal hernia in children is 99% congenital pathology. It is most common in very premature and premature infants, thus prevention of premature labor and good prenatal care (by obstetrician gynecologist) hypothetically minimizes the risk of inguinal hernia in kids in future.
2. Prevention of chronic constipation and bowel infection.
3. Early detection and dynamic observation of physiological hydrocele in newborns.
4. Prevention of hernia strangulation – if it is diagnosed, it is recommended to do a planned surgery 1-2 months after the diagnosis.

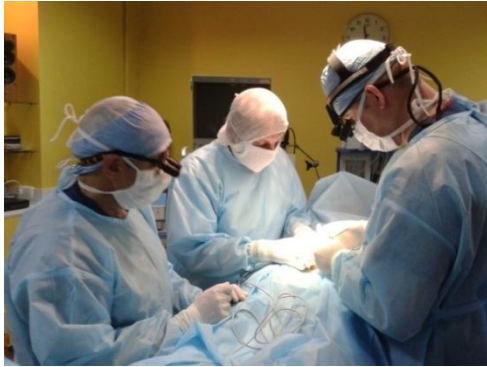
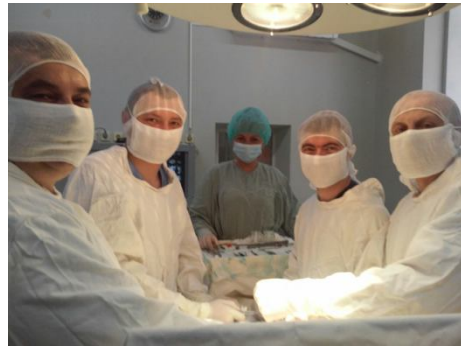
Urological services in the hospital.

700-800 surgeries every year;
more than 100 complicated reconstructive
surgeries on urinary and genital systems every year;
surgeries on newborns;
surgical treatment with maximum organ saving procedures.

Complex reconstructive surgeries in:

- hydronephrosis
- megaloureter
- vesicoureteral reflux (VUR)



- doubling of urinary tracts
- hypospadias;
- epispadias;
- hermaphroditism

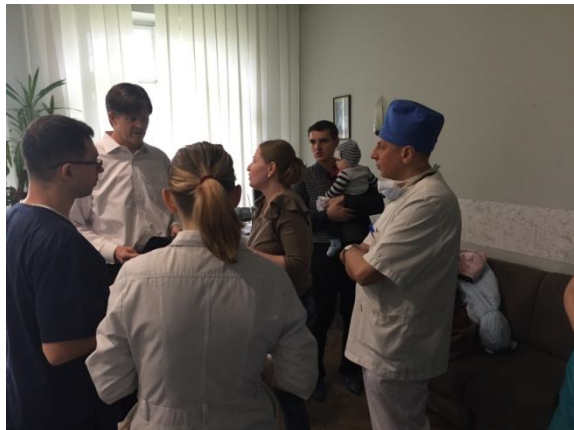Low invasive endoscopic and laparoscopic surgeries in:

- hydronephrosis;
- segment hydronephrosis;
- VUR;
- cystic kidney dysplasia;
- posterior urethral valve;

- abdominal cryptorchidism;
- varicocele;
- ureterocele.

We cooperate with pediatric urologists from:

the USA;
Canada;
Great Britain;
Poland



IMPORTANT ISSUES ABOUT THE BOYS (ADVICE FOR PARENTS).

Child birth is one of the most important events in our life. There are some general actions to be taken while taking care of any child to ensure his/her health and development. But there are more delicate, more intimate sex-dependent things to be addressed when the child is born.

Unlike those of girls, boys' genital organs have more complicated structure, more complicated formation process during intrauterine period and require more powerful hormone impact of fetal testosterone. Experiences show that gender-related "breaks



"in boys occur much more often.

It can be explained by the fact that development of female genital system is extremely sensitive to negative external and internal factors, and thus, it is more vulnerable. Birth of a boy requires more attention from the doctors of obstetric departments, pediatricians and family doctors, and sometimes better knowledge and more work on teaching parents childcare issues. First of all, it is necessary to pay attention to the size and symmetry of scrotum, presence of both testicles. To check this, one can tenderly palpate the right and left side of the scrotum and respective testicle.

It is necessary to once again examine inguinal area: whether there is no asymmetry because of tumour-like bulging; pay attention to the size and form of penis — for it not to be curved, foreskin slit, narrowing of its orifice, enlargement during urination, where there is opening of ureteral orifice. It is necessary to draw parents'

attention to the importance of observing the boy's urination, his behaviour during this process, width of urine stream, duration of urination, and if something catches their attention, consult the doctor dealing with urogenital "problems" of boys — pediatric urologist: it is better to be on the safe side than miss an impairment that may ruin the life of the child.

In the

practice of pediatric urologist the most common genital diseases in boys, mentioned by parents and requiring medical assistance, are phimosis, foreskin adhesions (synechias), hydrocele and funiculocoele, cryptorchidism (undescended testicle), hypospadias (opening of the external urethral orifice in an untypical place with penis deformation), varicocele.

Experienced pediatric urologists of "OHMATDYT" will help your sons in case of necessity.



Testicular pain.

One of the most common problems in boys so far is testicular pain which may be a sign of various diseases and in all cases requires consultation of a pediatric urologist or pediatric surgeon to prevent reproductive dysfunction of this organ.

Among the causes are:

- Inverted testis,
- Inflammation of testis or epididymitis,
- Hydatid torsion (appendix of testis),
- Infections (epidemic parotitis),
- Congenital diseases (cyst, hernia, hydrocyst, varicocele),
- Testicular tumors.

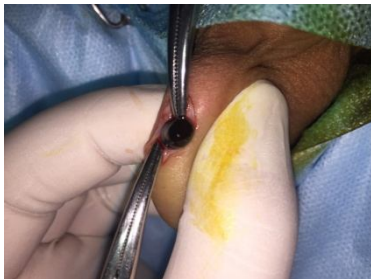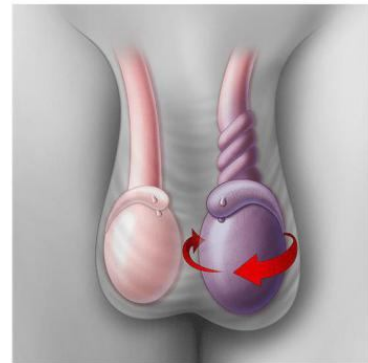
Inverted testis.

It should be considered that acute testicular pain in a child is caused by inverted testis unless diagnostic process shows a different cause. **The symptoms** are sudden pain that can be initially felt in the lower part of the abdomen and only later in scrotum, as well as sudden one-sided scrotum edema. Examination shows that testis is lifted into the upper part of the scrotum or is in a horizontal position. Meanwhile the boys may be restless, walk with their legs apart, have repeated fits of nausea. But at the initial stage strong testicular pain can be the only manifestation.

Hydatid and epididymal torsion, as well as epididymitis (epididymis inflammation) may resemble inverted testis, but clinical picture is developing slower.

Quite frequently differential diagnostics can be done only during surgery.

The child is hospitalized with a diagnosis "acute testis condition", which is a combined notion.



Treatment of inverted testis is an urgent surgery aimed at detorsion and fixation of testes in the middle of the scrotum (during first 6-8 hours from the onset of a

disease). Without timely diagnostics and belated surgery testis necrosis can be found and removed. In case of hydatid torsion the latter is removed and, if it is necessary, serous testicular cavity is drained, if there are signs of secondary orchoepididymitis.

Epididymitis (epididymis inflammation).

Swelling and painfulness are noted in the area of the epididymis, but the testicle can also be painful. The scrotum is often swollen, red and hot to the touch. Among the common symptoms of urinary disorders are pain, burning and frequent urination.

The most common cause of this condition is a urinary tract infection. In children epididymitis is most likely caused by infected urine entering the vas deferens. Particular attention should be paid to children with enuresis and difficulty urinating.



In all age groups of patients surethra manipulations, such as constant catheterization, are epididymitis development risk factors.

Initial treatment in children is conservative and involves antibiotics and local therapy. No effect is indication to surgery.

Orchitis (testis inflammation).

The clinical picture resembles epididymitis. Edema is located exclusively in the testicles. Orchitis is very rare in those countries where parotitis has disappeared due to vaccination, but may be associated with epididymitis (orchoepididymitis). Differential diagnostics of orchitis and inverted testis

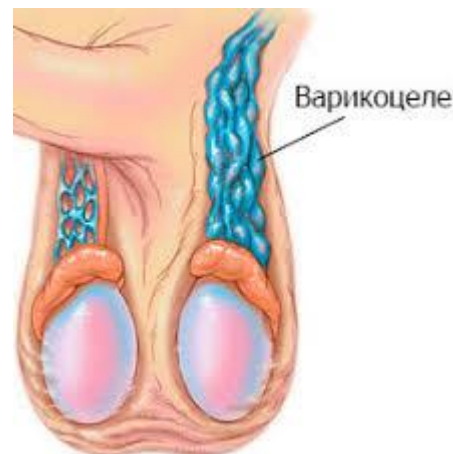sometimes is quite complicated (in case of the smallest doubts, the patient should be immediately taken to hospital).

Varicocele.

In older children there are symptoms of visible varicose veins of the pampiniform plexus of the spermatic cord in the left part of the scrotum, and sometimes testicular pain. In the majority of cases the disease causes fertility decrease. As a rule, it needs surgical treatment.

It is worth noting that testicular pain can be a sign of tumour or other serious diseases, therefore, the child should be examined by a pediatric urologist.

Every year more than 100 surgical interventions on testicular pain syndrome and signs of "inflamed" scrotum are successfully performed in LRCC "OHMATDYT". Later the boys are supervised by the pediatric urologist.

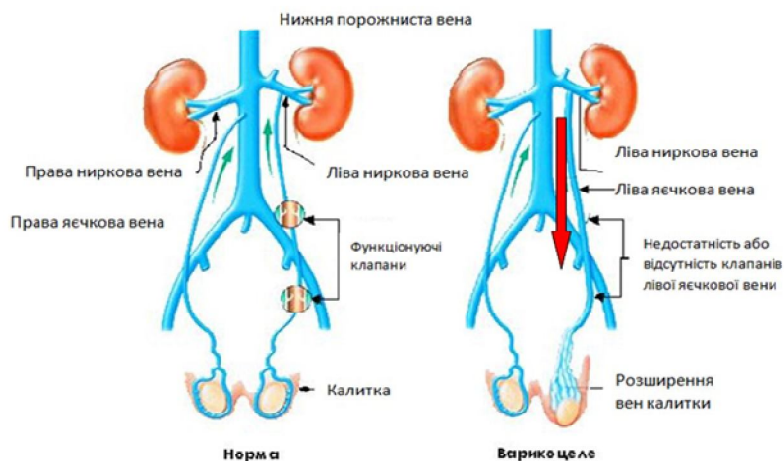


Varicocele

Varicocele is an enlargement of the testicular vein due to the impairment of venous outflow.

Most frequently this pathology appears in teenage boys and in the majority of cases develops on the left. It occurs due to the fact that the left testicular vein in all men falls into the left renal vein, and in case of vein patency impairment (congenital narrowing of the vein, vein compression in the aorta mesenteric "clamp") there is a massive discharge of venous blood from the renal vein pool into the pampiniform plexus of the left spermatic cord.

What are the symptoms of the disease?



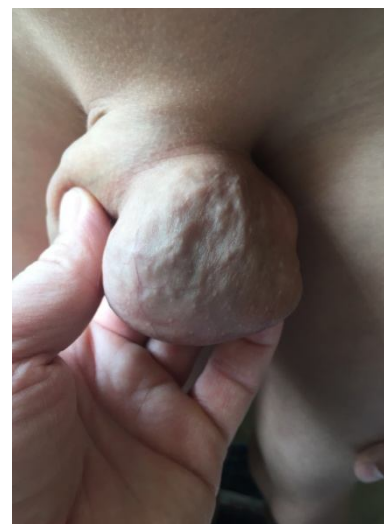As a rule, there are no complaints. Sometimes boys feel discomfort or heaviness in the scrotum area. Usually pathology is detected in teenage age during medical checkup, in military recruitment office, or during groin area examination by the teenagers themselves.

The main symptom of varicocele is an enlargement in the size of the left half of the scrotum. Examination often shows varicose veins of the left testicle, which are well contoured in the form of a "plexus of worms" through the skin. Ultrasound diagnosis of the left kidney vessels and left testicle is used for additional examination. In children there is no sperm research, which is

crucial for determining treatment tactics in adults. This is done from the age of 18.

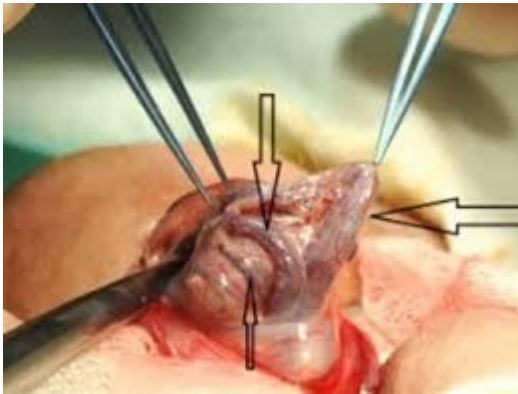
Why is this disease so serious?

Testicles perform two main functions: sperm synthesis for reproduction purposes and synthesis of testosterone – extremely important hormone.



Varicocele does not limit working capacity and does not reduce the quality of life. However, there is one crucial issue! Typical complication of varicocele is male infertility.

Is surgery always necessary?

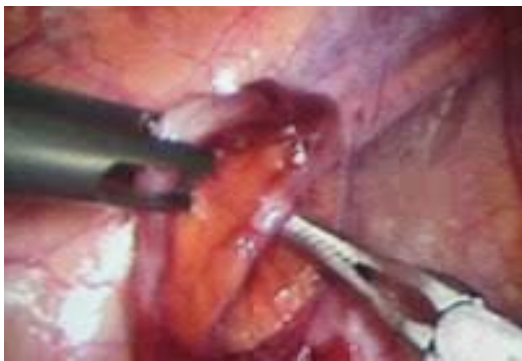

A child should be examined by a pediatric urologist. In mild cases surgery is not recommended. Absolute indications for the surgery are the following ones: decrease of testicle size, constant pain syndrome, severe varicocele.

Every case requires individual approach to examination and treatment. Surgery can be performed with subinguinal mini-access (Marmar

technique) or with laparoscopy.

Pediatric urologists of LRCCH "OHMATDYT" know perfectly well all the surgical techniques used to treat these conditions.



Hydrocele and funiculocele

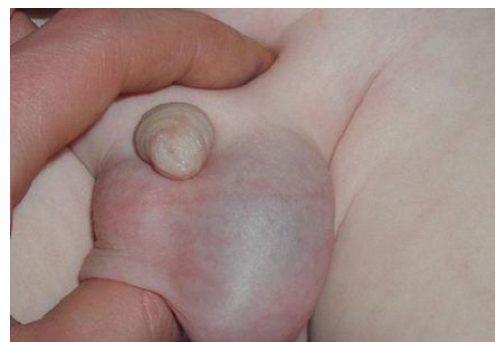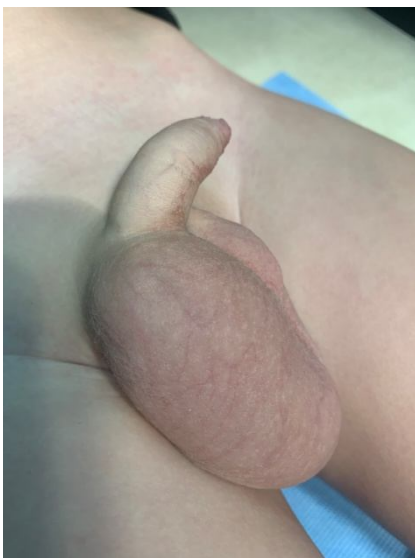Hydrocele and funiculocele are very common childhood diseases, which are associated with the process of intrauterine immersion of the testicle from the abdominal cavity of the fetus into the scrotum, when canal of peritoneal diverticulum remains open in the spermatic cord. With the birth of a boy, when the process of the testicle descending into the scrotum is over, the peritoneal diverticulum should normally close – get obliterated. If this does not happen, then there is a connection between the serous cavity of the testicle and the abdominal cavity, there is serous fluid flowing from the abdomen into the testicular cavity – resulting in hydrocele.

What is especially serious about hydrocele and funiculocele?

High pressure of fluid leads to the compression of testicle and vessels in the spermatic cord, lymph and blood circulation impairments in the very testicle. Moreover, presence of fluid affects temperature regime of the environment around testicle, to which the testicle is very sensitive. If medical aid is provided untimely, sclerotic process will develop in the testicular tissue, and big hydrocele can lead to the testicular atrophy. In its turn, it may lead to serious problems in adulthood.

Clinic and diagnostics

Generally, disease is diagnosed after birth already in the maternity unit and it has even,

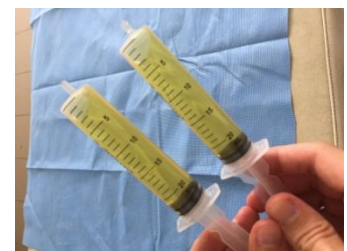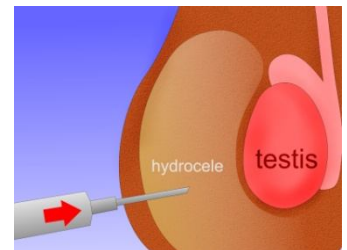


“quiet”course of the disease. Hydroceleandfuniculocelecan be unilateral (more often) or bilateral. Itsmanifestationarescrotumpartsenlargement, and with bilateral hydrocele — enlargement of the whole scrotum. In most cases palpation shows elastic consistency. Often after sleep its size decreases or it disappears completely (the fluid has passed into the abdominal cavity), but by the end of the day hydrocele restores its previous volume. As a rule, the child's condition is not disturbed. Hydrocele can also be acute when it becomes tense due to a mismatch between the volume of fluid coming from the abdomen and the capacity of the hydrocele cavity. The child becomes restless, loses appetite, moves his legs. Hydrocele size increases significantly, and on palpation it is very hard, dense, tense. In such cases, it is necessary to distinguish between severe hydrocele and funiculocele from strangulation of the inguinal or inguinal-scrotal hernia.

Sometimes there are cases when the symptoms of hydrocele and funiculocele appear not when a child is born, but later - after 1-2 years of age, and parents often ask: "How could this happen, why?". Doctors should explain that sometimes congenital hydrocele is in an inactive state, when the walls of the peritoneal diverticulum canal from birth are close to each other, touch each other, stick together, but are not glued, and the canal is not skinned over. It exists, but it does not function. Any factorsresulting in an increase in intra-abdominal pressure (coughing, constipation, lifting heavy objects, etc.) and sometimes trauma of the groin area lead to the ungluing of the canal walls, and abdominal fluid flowing to the testicle.

Treatment

If the course of varicocele is favorable, then self-healing of a child aged 1-1.5 years may occur. If the disease has not disappeared after this period or varicocele first appeared after the age of 1 year, it is necessary to carry out surgical treatment. Children with severe or tensevaricocele who are under 1 year old are recommended a puncture of the varicocele cavity with fluid evacuation and application of a compressive bandage to the scrotum. Sometimes it is necessary to perform repeated punctures. If it does not produce any effect and varicocele progresses, thenpediatric urologist decides on surgical treatment at an earlier age (up to 1 year of age). Pediatric urologists at LRCCH “OHMATDYT” know all the surgical techniques to treat this disease.



Cryptorchidism

Thisisoneofthemostcommongenitalabnormalitiesin children, which is characterizedby the absenceof one or both testes in the scrotum. Approximately 4–5% ofboysarediagnosedundescendedtestesatbirth, butinmorethanhalfofcases theprocessof testiclesdescentinto thescrotumcontinuesduring the first 3 months of life, after which the frequency of the congenital cryptorchidismis 1–2%.



Why is cryptorchidism a serious condition?

The danger of this disease is that location of the testicle or testicles in an atypical place leads to their mechanical compression by the surrounding tissues (which is not the case in the condition sac - scrotum) and to the violation of temperature (the scrotum temperature is always below the groin area temperature, abdomen temperature or other places where the testicle may stop). These are mechanical and temperature factors that cause dystrophy and atrophy of the germinal epithelium, which is responsible for the formation and maturation of germ cells, and hence for future offspring, and these factors cause dysfunction of cells that produce male sex hormones and give the body "masculine" qualities. In addition, the disease can be complicated by the development of malignant tumor after puberty in caseadequate medical care is provideduntimely.

Normally testicle descent from the abdomen to the scrotum takes place in a natural way. If under the influence of some factors it stopped in the abdomen, we observe abdominal disease type (abdominal retention), if in the inguinal canal — inguinal type (inguinal retention).

Clinical signs and diagnostics

Primary examination of a child in the maternity care unit

may show signs of cryptorchidism: absence of one or both testes in the scrotum, as well as underdevelopment of part or the entire scrotum (when testicle is in the scrotum, it stimulates its growth).

If the boy has inguinal form of cryptorchidism, then the testicle may be palpable in the corresponding inguinal area.

If the testicle is in the abdomen, it is not palpable.

Sometimes parents pay attention to the fact that there were testicles in the scrotum, but then they disappeared,

and from time to time (during sleep or especially in warm bath)

they descend. It is the so-called false cryptorchidism or pseudo-

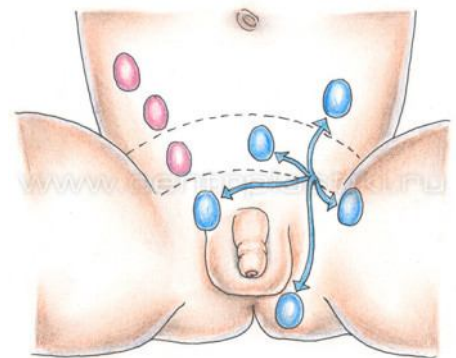
cryptorchidism (testicle retraction), which is related to excessive agitation of the nervous system and spasm of a muscle, which lifts the testicle, and does not require surgical treatment.

If a testicle is not palpable, then to better understand the situation the doctor can use ultrasound diagnostics, laparoscopy, hormonal tests and Rg-graphy (angiography, CT, nuclear medicine imaging).

As a rule, when the process is unilateral, there is no delay in sexual development.

Such a delay can be observed in bilateral disease.

Boys with suspicion for cryptorchidism should be referred to the pediatric urologist, who after examination of a child will administer further diagnostic methods and the course of treatment.



Treatment

The final objective of the treatment is testicle descent into scrotum.

Cryptorchidism treatment should be completed till the 1st year of life (maximum till the 2nd year of life).

The critical stage of germ cell maturation in the testicle occurs during the second half of the 1st year of life, therefore treatment should be started from the age of 6 months.

It also prevents potential malignant transformation of the undescended testicle tissue in the future.

Surgical treatment is the major treatment technique for the disease.

Surgery on descending the testicle into the scrotum is called orchidopexy.

In abdominal form of cryptorchidism,

if it is technically impossible to bring the testicle down to the bottom of the scrotum because of the short vessel of the spermatic cord, surgical treatment will have two stages: 1st stage — the testicle is taken from the abdomen and is

left beyond the boundaries of the external inguinal ring, 2nd stage — after 8–12 months the testicle is descended on the bottom of the scrotum.

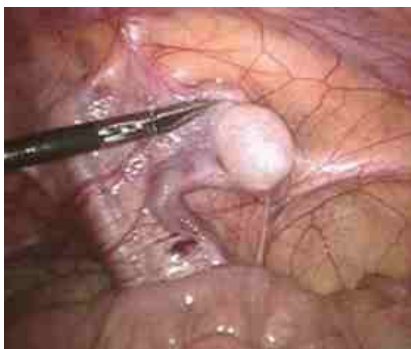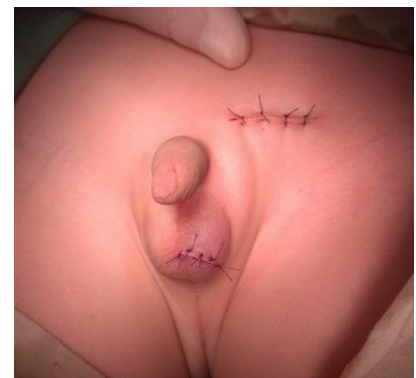
In abdominal form of cryptorchidism we also use laparoscopic surgery by Fowler-Stephens technique or Shehata, which are also performed in two stages.

Hormone therapy can be used as the first stage in bilateral cryptorchidism, in unilateral - if there are endocrine disorders, as well as in false cryptorchidism.

Cryptorchidism is considered a pressing problem in modern medicine and often requires joint efforts of a pediatric urologist, pediatric endocrinologist, and sometimes a geneticist.

Surgical treatment should be performed by a pediatric urologist, who has

extensive experience in such delicate surgeries, the success of which will influence the future health and happy life of the adult man.



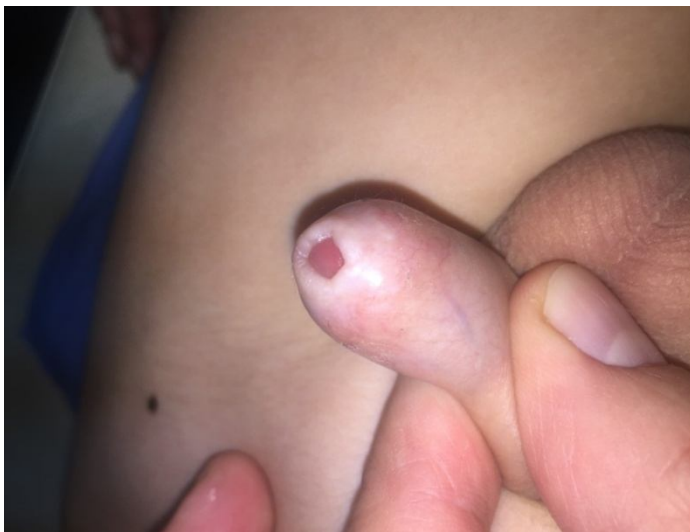Phimosis

Practically all the boys are born with physiological foreskin narrowing — this is the condition when it has a cone form, narrow orifice and that is why it is not moved from the penis head, and constantly covers it.

Very often in this case there are adhesions between penis head surface and internal surface of the foreskin, the so called preputial sheath synechias. Nature not only created a boy in a beautiful and wise way according to God's plan, but also took care of the further development of the future man. The normal process of penis development is natural and spontaneous and is accompanied by maturation of the foreskin tissues - it becomes less dense, more elastic, its orifice expands, the membranes of the preputial sheath disappear, and therefore free opening of the penis head can occur before puberty. The duration of this process is quite variable, and in different children it happens differently, but its main elements should normally occur at an early age (in the first 2-3 years of life), although in 20% of boys physiological narrowing of the foreskin is observed at the age of 5 years, and synechiae of the preputial sheath may completely dissipate only at 8-10 years of age.



In contrast to physiological narrowing, phimosis is a disease and it is characterized by the impairment of urination due to a serious narrowing of the foreskin orifice. If an infant boy has such a significant narrowing of the preputial sheath opening, which makes it impossible to expose the head of the penis and complicates the act of urination, then we are dealing with congenital phimosis. However, if from the moment of the child's birth urination was normal, and with time, due to the infection of a preputial sheath and inflammatory process development, the boy developed these signs of phimosis, then the diagnosis will be acquired phimosis.




Pediatric urologists also distinguish between atrophic phimosis, when the foreskin is short and covers penis head in the form of a "cloak", and hypertrophic phimosis, when the skin is long, overdeveloped and looks like a "proboscis", and therefore not only the orifice is narrowed, but so is the entire canal.

Among the main manifestations of phimosis in children are: difficulty urinating with a thin stream, prolonged urination, the child is strained, urination is painful, the child is restless and may be crying, constant discomfort and itching in the genital area, it is impossible to expose the penis head, foreskin

orifice is severely narrowed, and sometimes it is not visible at all, every time during urination the preputial sheath is inflated. Often one can observe scar tissue changes in the area of the ring ("white ring"). Complications of phimosis are purulent balanoposthitis (inflammation of the penis head), paraphimosis (clamped head), urinary tract infections.

With timely consultation of a specialist, most boys do not need surgery. Pediatric urologist determines the tactics and scope of therapy individually in each case and for each child.

The essence of conservative therapy of phimosis is bloodless dilation of the foreskin ring and elimination of preputial sheath synechiae under local anesthesia.

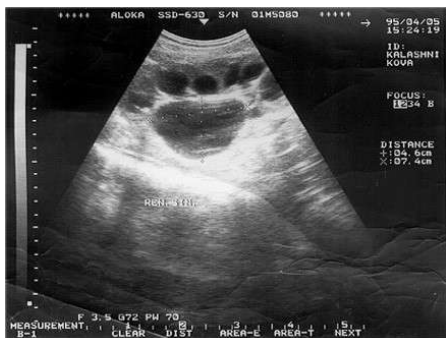

Among the surgical methods of phimosis treatment the most commonly used surgery is circumcision (excision of the foreskin leaves) and surgery according to Roser (plastic of the foreskin with its preservation).

Hydronephrosis.

It is malformation of the kidneys, which is characterized by enlargement and expansion of the renal cavity system due to impaired patency of the first part of ureter. Without proper treatment this can cause progressive atrophy of the renal parenchyma with loss of its function. In cases of uretero hydronephrosis, there is an expansion of both the ureter and the renal pelvis and calices, which occurs due to impaired outflow of urine along the ureter.

How can this disease be detected?



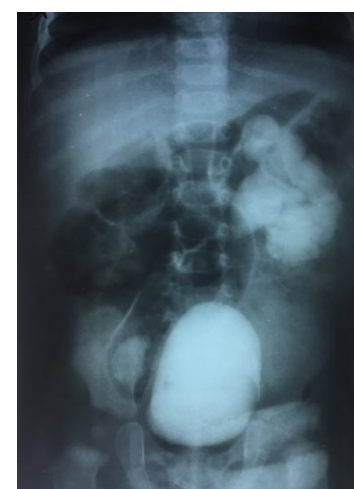
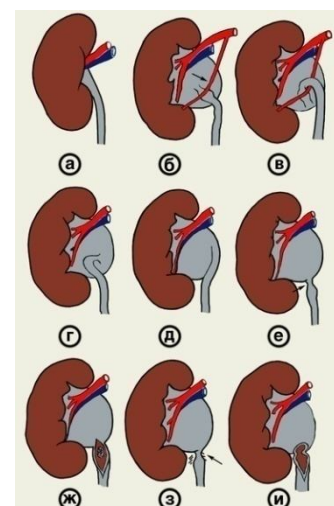
In the early stages this disease is usually asymptomatic. All laboratory parameters (tests) may be normal. The disease is most often detected during abdominal ultrasound done to detect other problems or for prevention purposes. Symptoms of this disease can also be attacks of lumbar pain or frequent urinary tract infections. However, timely detection of hydronephrosis in the early stages makes it possible to save the organ.

What causes the disease?

In a healthy child urine produced in the kidneys flows down the urinary tract to the bladder. In case of narrowing of the ureter or its external compression, for example, by additional vessel, there is an impairment of the urine outflow. This is compensated by stretching of the renal pelvis and calices, which significantly increase in size. At the same time pressure in renal cavity increases, which affects renal tissue so much that it atrophies. The rate of parenchyma atrophy is directly proportional to the degree of narrowing and the degree of expansion of the pelvicalyceal system of the kidney.

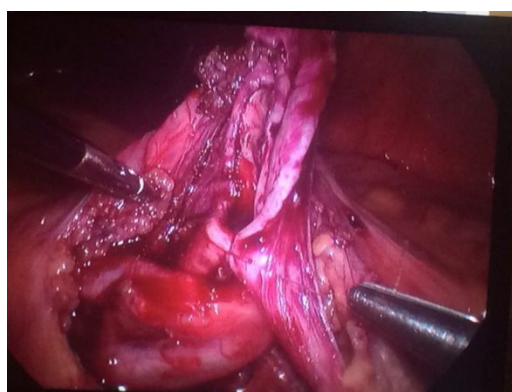How can this problem be solved?

The problem described above can only be solved by removing the narrowing between the renal pelvis and the ureter. But surgery is not always necessary. In some cases, in the initial stages of hydronephrosis, the pathology disappears on its own. To make a conclusion about the necessity of a surgery, a urologist uses additional methods of examination - ultrasound examination of the kidneys and bladder, X-ray diagnosis - excretory urography; in some cases, renoscintigraphy, magnetic resonance imaging (MRI), computed tomography (CT). The first two methods provide a more accurate assessment of the structure of the affected kidney, and nephroscintigraphy provides accurate information about the function of the renal filter.



What if the child needs a surgery?

The goal is to restore patency of urinary tract. One needs to remove the narrowing and restore the proper structure of the renal pelvis and ureters. The surgery is performed on individual indications by open (through a small



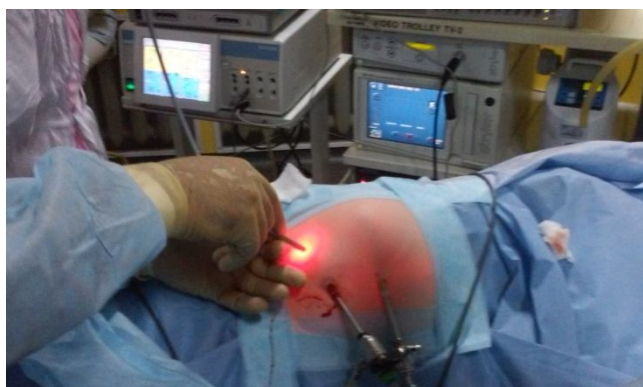incision on the side) or laparoscopic (several mini-incisions) methods. The doctors of "OHMATDIT" have excellent knowledge of all types of surgical correction of this pathology. Early surgery reduces the degree of loss of kidney function and accelerates its recovery.

LAPAROSCOPIC NEPHROUROLOGY IN CHILDREN.

In recent years, pediatric surgery and urology in Ukraine has gained experience in performing laparoscopic surgeries to treat children with urological pathology, in particular, with various malformations of kidneys and urinary tract.

"OHMATDYT" is the first hospital in Ukraine where laparoscopic nephrourological surgery was performed in a child.

Doctors from "OHMATDYT" gained experience in performing such operations with the support and experience of Doctor of Medicine, Professor Dariusz Patkowski (Wroclaw Medical Academy (Poland)). With professor's assistance the first laparoscopic surgeries in children with congenital malformations of the kidneys and urinary tract were performed in 2011. A highlight for the clinic's urologists was the joint performance of laparoscopic surgery together with the UK's leading pediatric urologist from the Great Ormond Street Hospital for Children (London) Professor Abraham Cherian in March and September 2016.

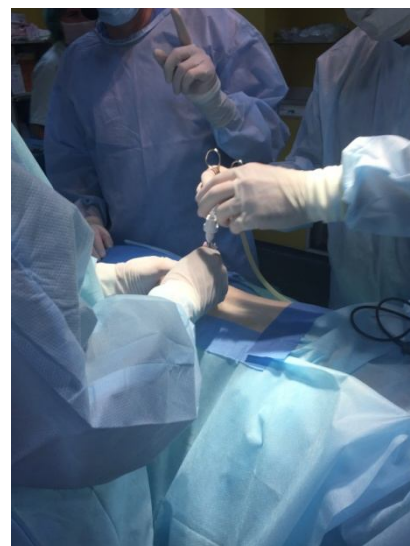


Thus, thanks to our colleagues it is already for more than a decade that laparoscopic nephrourological surgeries have been performed in the Lviv Regional Children's Clinical

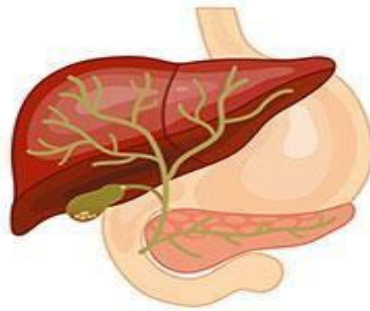
Hospital "OHMATDYT", in particular, in case of the following malformations: hydronephrosis, segmental ureterohydronephrosis with loss of function of one of the segments, renal multicystosis, VUR, renal cysts, etc. Operated children were from 4 months up to 17 years of age. The hospital boasts of the most extensive experience in performing such surgeries in Ukraine.

Laparoscopic access creates good conditions for examination and mobilization of all anatomical elements of the kidney (both renal poles, both edges of the kidney, vascular pedicle, the entire ureter). Such important technical elements of laparoscopy as good lighting and intraoperative magnification provide a wide field of view and enable the surgeons efficiently perform the most complicated aspects of the surgery. Laparoscopic surgeries have excellent cosmetic effect. In most patients the postoperative period went smoothly. There was no severe pain syndrome. The children were walking from the 2nd day after surgery and were released from hospital during 4-7 day period.

Laparoscopic technique **is more and more sought after in** nephrourological surgeries in our hospital.



CHOLELITHIASIS



Cholelithiasis is an illness that develops as a result of the formation and gathering of gallbladder stones. Routine abdominal ultrasound allows for detection of gallbladder stones in approximately 1/5 of population, in various age groups. Cholelithiasis is more prevalent in women, obese patients, especially those on a constant diet and with diabetes. Moreover, the risk of cholelithiasis is increased in patients with liver cirrhosis and coronary disease, multiple pregnancies, increased level of triglycerides, state after surgical procedures (gastric resection, short intestine syndrome). Cholelithiasis is asymptomatic in about 50% of patients.

Considering the above, it is apparent that we have control over only some of these factors. Cholelithiasis prevention includes lifestyle changes. We recommend adjusting calorie intake, exercising at least 30 minutes per day to gradually decrease the bodyweight to the optimal level (1-2 kg/week). Medications that increase bile production, e.g. Raphacholin, in case of cholelithiasis, should be used carefully. These medications facilitate bile evacuation from the gallbladder. However, they may cause the impaction of the stones in the cystic duct or bile ducts. This may cause biliary colic attack (gallstone attack) and possibly lead to acute cholecystitis, cholangitis or even acute pancreatitis. Conservative treatment using ursodeoxycholic acid (UDCA) could dissolve small cholesterol gallstones without calcifications.

The most frequent symptoms of cholelithiasis include:

- pain in the right upper quadrant of the abdomen, sometimes radiating to the scapular area, with concomitant nausea, lasting from 30 minutes to about 6 hours,

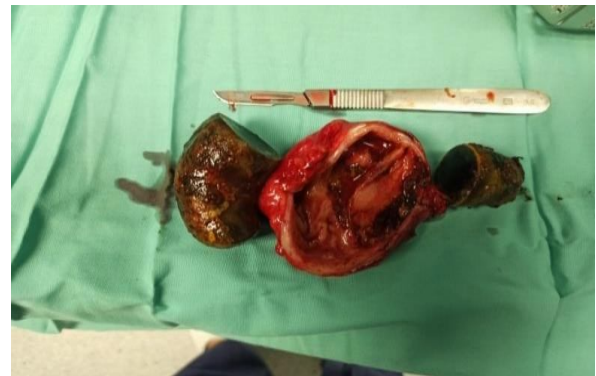
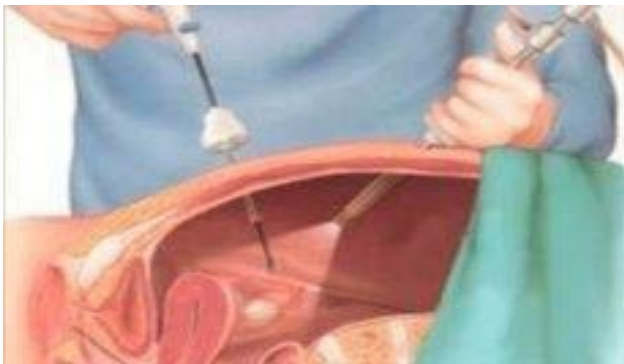
- the pain appears after meals, the patient sees a correlation between eating certain types of food and the onset of pain.

If the pain is not relieved by taking painkillers, you should contact the doctor immediately. It may be a sign of developing acute cholecystitis and you might need a surgical treatment.

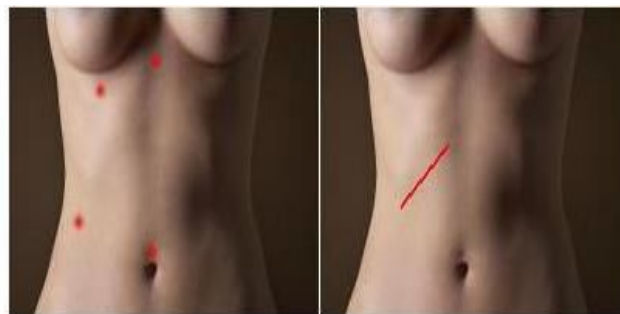About 30% of patients do not experience typical colic pain, but only non-specific discomfort, nausea, bloating, fullness in the abdominal area. Similar symptoms appear in patients suffering from several other conditions, which is why if you experience such symptoms, you should consult with a surgeon to reach a correct diagnosis and qualify for appropriate treatment.

In the General Surgery Department named after dr Jerzy Olszewski in the Józef Psarski Mazovian Specialist Hospital in Ostrołęka, cholecystectomy procedures are performed, in most cases laparoscopically and in some cases classically (by open surgery).



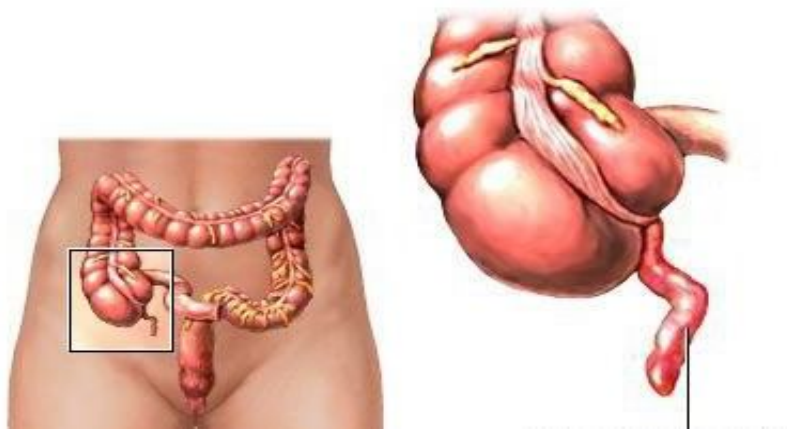
In the case of laparoscopic cholecystectomy 3 or 4 small incisions are made (7-15 mm) in the abdominal area. Through these incisions, the trocars are introduced inside the peritoneum. Thanks to a special camera and a set of device it is possible to locate the gallbladder and excise it.

In the case of the classical method- laparotomy, the incision on the abdominal wall is about 15-20 cm long. The incision allows to cut out the gallbladder with the stones.



Moreover, laparotomy enables to correctly evaluate other existing pathologies in the peritoneal cavity. In more complex cases, when the intraoperative difficulties occur, with the identification of biliary tree components and vessels of the hepatic hilum, it may be necessary to change the laparoscopic access to the open surgery method. In the case of existing contraindications to the laparoscopic approach, it is also necessary to perform open surgery. In the case of planned laparoscopic cholecystectomy, after the surgery, the patient may leave the hospital ward within 48 hours after the procedure. The patients are later evaluated on the control visit in the surgical outpatient clinic.

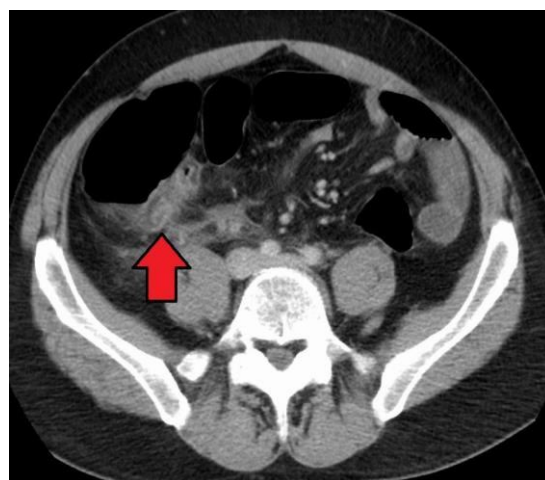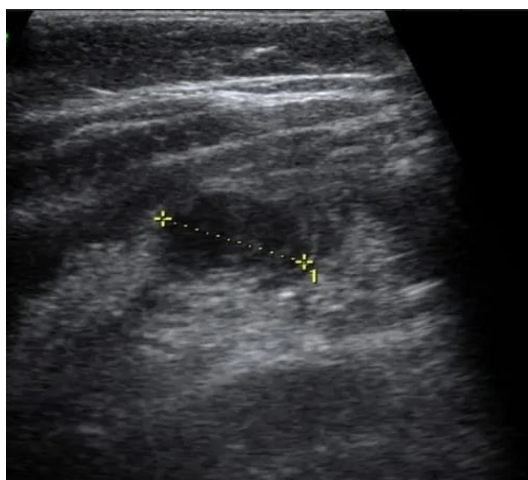ACUTE APPENDICITIS



Acute appendicitis is one of the most common causes of abdominal pain. It can appear in patients of any age, it affects both sexes equally often. In Poland, appendicitis is the most common indication for urgent surgery. Acute appendicitis is caused by occlusion of the appendix with e.g. faecal stones, pinworm infection (enterobiasis) or enlarged lymph node. Numerous studies suggest that insufficient fibre intake in a diet increases the risk of acute appendicitis. We should therefore remember about the right diet.

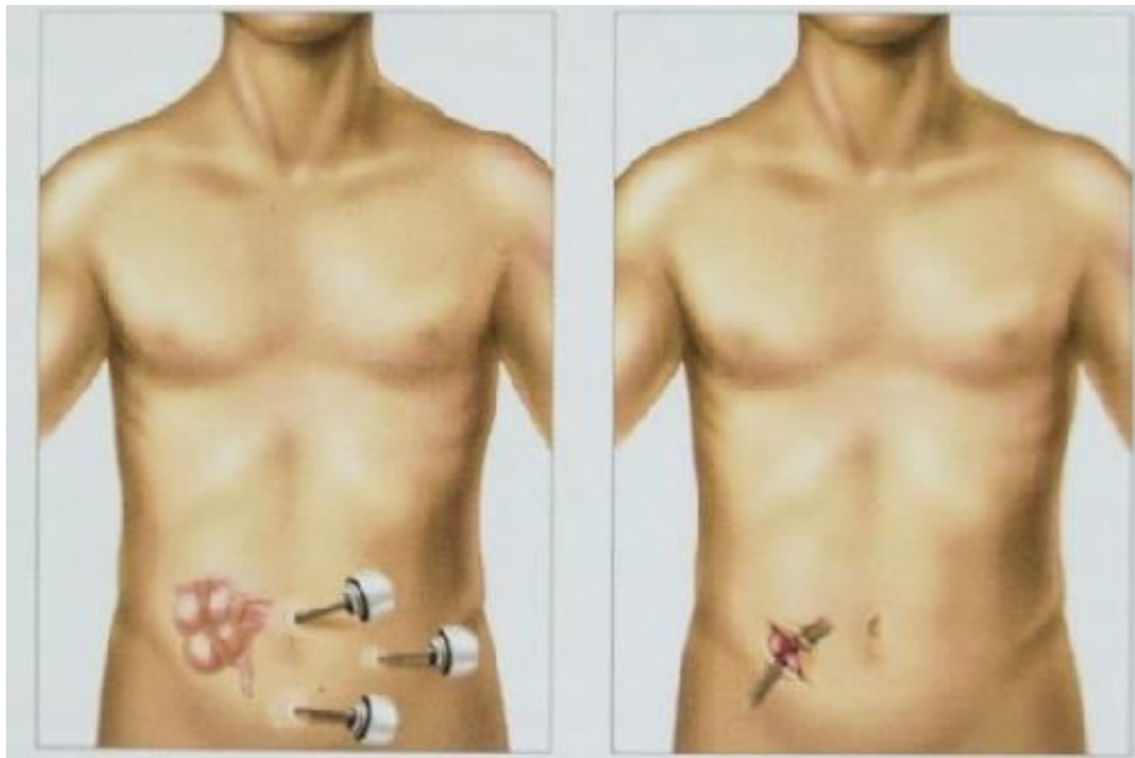
The most common symptoms of acute appendicitis include:

- primarily the pain is constant, located in the upper quadrants or the umbilical area, later the pain is relocated to the right lower abdominal quadrant,
- coexisting lack of appetite, nausea, sometimes accompanied by vomiting, constipation,
- usually accompanied by fever.

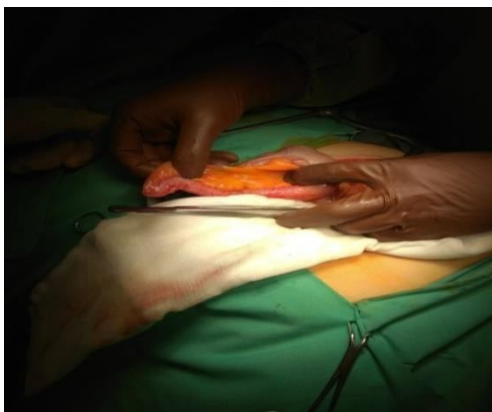

Clinical manifestation can be diverse from previously described, owing to differences in the anatomical location of the appendix. If the abovementioned symptoms appear, you should consult with a surgeon. Diagnosis of acute appendicitis based on medical examination may not be easy, even for experienced specialists, other abdominal abnormalities may have a similar manifestation. For this reason complementary tests, such as laboratory tests, abdominal ultrasound and even CT scan with contrast are often performed to facilitate the diagnosis.

In the General Surgery Department named after dr Jerzy Olszewski in the Józef Psarski Mazovian Specialist Hospital in Ostrołęka, appendectomy is performed laparoscopically and in some cases with the open classic method.



Laparoscopic appendectomy access is created with 3 small incisions (7-15 mm) on the abdominal wall which allows introducing trocars inside the abdominal cavity. Laparoscopic camera and other device allow to precisely locate the appendix and excise it. Moreover, laparoscopic access allows differentiating appendicitis from other pathologies of the peritoneum.

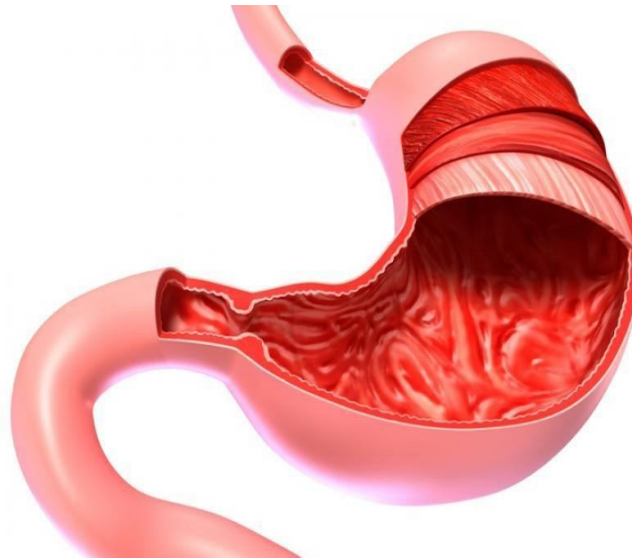

In more complex cases, such as a perforated appendix, abscess formation or diffuse peritonitis, it may be necessary to convert to open-access surgery.

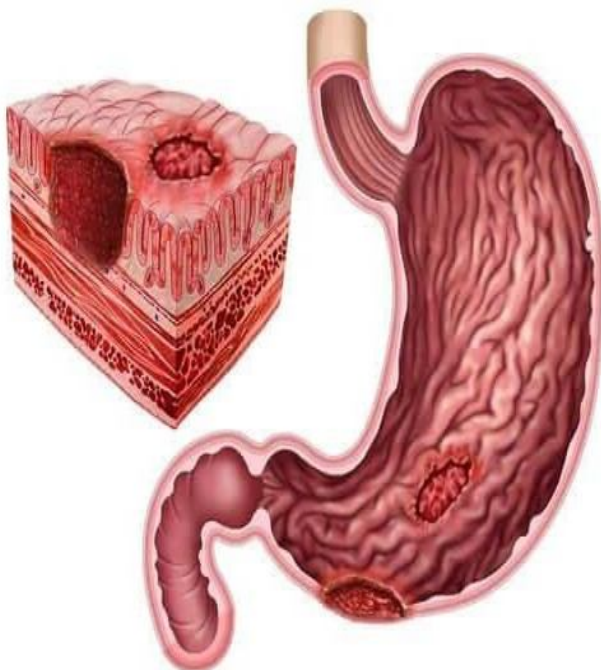
Sometimes the size of the appendix may be impressive- in this case, the appendix is about 15 cm long.

In case of uncomplicated appendicitis managed surgically, the patient may leave the Ward within 48 hours after surgery. After discharge, the patient is monitored on the control visit in the outpatient surgical care unit.

PEPTIC ULCER PERFORATION

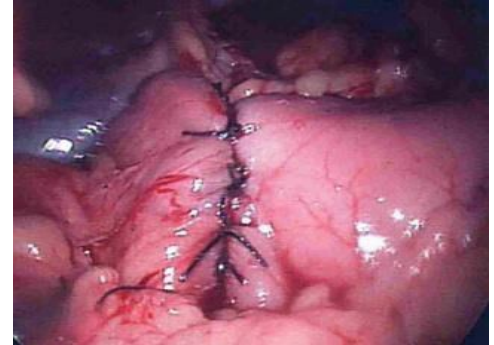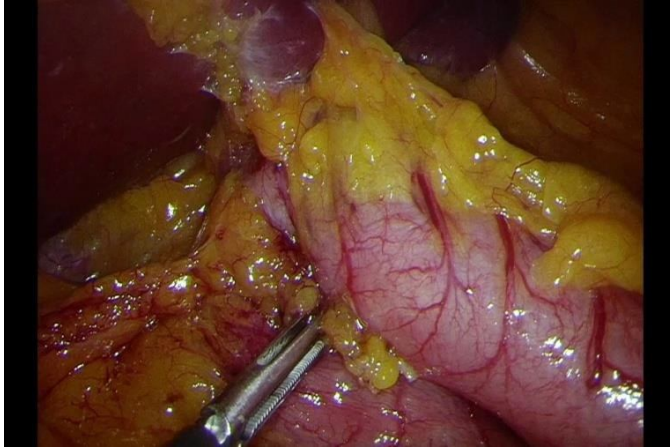


Untreated peptic ulcer disease may lead to gastrointestinal tract perforation, the outflow of the gastric content to the peritoneal cavity and result in acute peritonitis, which is an indication for urgent surgical treatment. Most frequently perforation is located in the duodenum (90%).

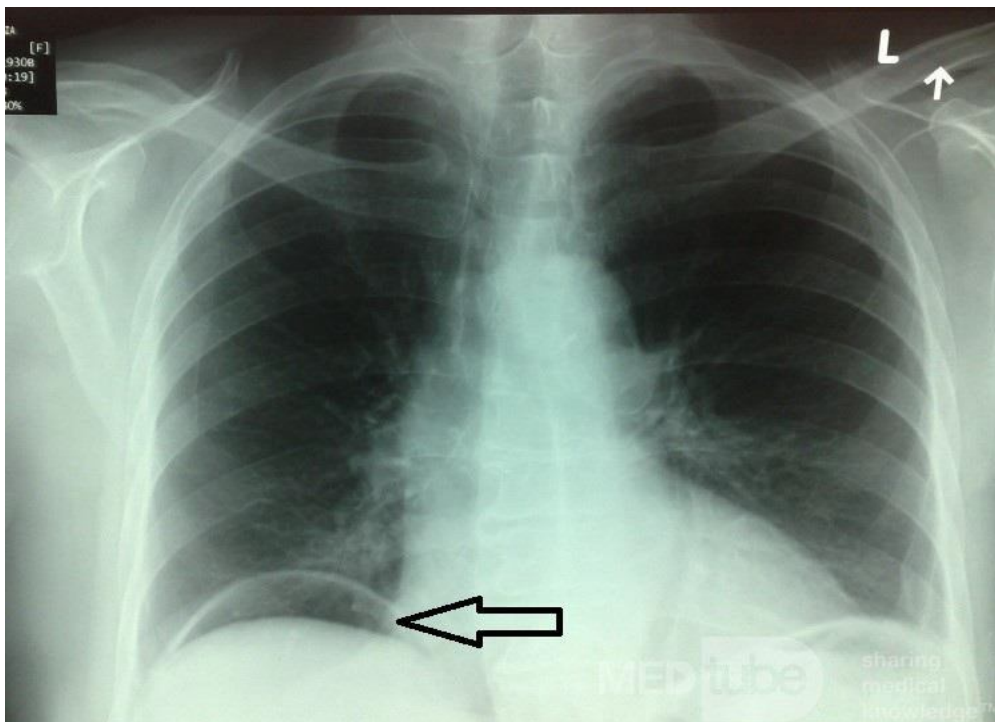


The most prevalent clinical picture of peptic ulcer perforation is a sudden, intense pain in the whole abdomen, prevailing despite taking pain medication. Such symptoms should urge you to seek immediate medical help in the ER, to quickly reach a diagnosis and perform surgery. Peptic ulcer perforation is a life-threatening condition, which should be timely treated. Even with surgical treatment, mortality of patients with perforation reaches 10 to 20%.

Surgical treatment involves suturing the perforated fragment of the stomach and the duodenum, resection of part of the stomach and/or truncal vagotomy (a procedure of cutting the trunks of vagus nerves which are located under the diaphragm) and introducing pharmacological treatment.



In the General Surgery Department named after dr Jerzy Olszewski in the Józef Psarski Mazovian Specialist Hospital in Ostrołęka, the procedure can be performed either laparoscopically or classically. Duration of hospitalisation depends on the general condition of the patient and the time from symptoms onset to surgical management.



On the right, visible subdiaphragmatic gas constitutes a typical display of gastrointestinal tract perforation on chest X-ray.

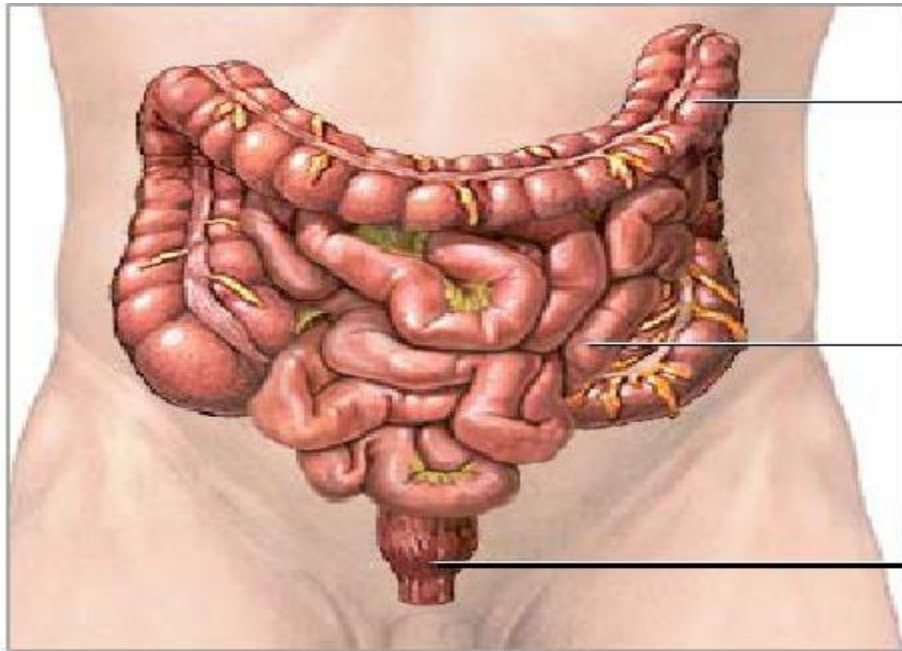
Peptic ulcer disease is diagnosed with the endoscopic examination- gastroscopy. Helicobacter pylori bacteria is responsible for 70-90% of peptic ulcers, but only 10% of H.pylori carriers develop an ulcer. Other factors that contribute to ulcer formation are tobacco smoking, taking excessive amounts of NSAIDs such as aspirin, diclofenac, ibuprofen, ketoprofen, naproxen. Alcohol intake does not cause ulcer formation, but alcohol excess may worsen the course of the disease and treating such patients is more demanding, because of poor wound healing.

Timely diagnosis and pharmacological treatment is an adequate management method for peptic ulcer. It enables to fully control the course of the disease, treat it and prevent the complications such as perforation. Pharmacological treatment for the eradication of H.pylori in combination with a proper diet (peptic ulcer diet) is highly effective.

1. Meals should be eaten regularly, every 3-4 hours, in small portions.
2. It is optimal to eat the last meal before sleep.
3. Meals are healthier when eaten without hurry and nervousness. You should chew bits of food thoroughly.
4. Food should be easy to digest, non-irritating to the gastric mucosa, not inducing oversecretion of gastric acid and well-absorbed.
5. The dishes should be of moderate temperature and fresh-made.
6. We recommend reducing or eliminating salt consumption as well as spicy seasonings and vinegar.
7. Products rich in fat should be avoided.
8. The reduced consumption of fibre and products that cause bloating relieves gastric symptoms.
9. It is healthier to refrain from vices: coffee, alcohol and tobacco smoking.
10. You should avoid fried dishes and use more healthy processing methods.
11. You should not use non-steroidal anti-inflammatory drugs.
12. You should eliminate all carbonated beverages and products containing caffeine.
13. You should take medications with mineral water.

If you experience burning pain in the epigastric area, discomfort on an empty stomach (so-called hunger pain), which is alleviated by food intake or antacid admission, you should report to your family doctor to conduct a preliminary diagnosis in this direction.

COLORECTAL CANCER



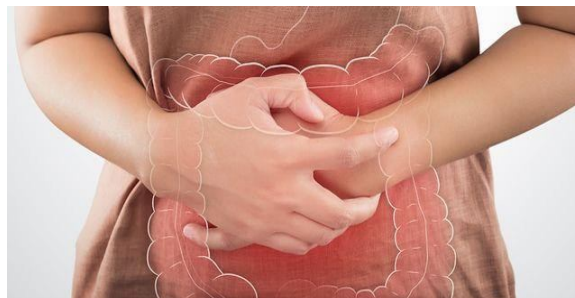Colorectal cancer is the third most prevalent cancer in men and the 4th in women. It is an insidious disease, which can remain asymptomatic for years. About 90% of cases of colorectal cancer develop sporadically, only 5-10% have a genetic background. Several risk factors increase the probability of being affected by this cancer. Some of them may and should be controlled.

The risk factors of colorectal cancer include:

- age over 50
- metabolic syndrome, including abdominal obesity, type 2 diabetes, hypertension, low level of HDL (high-density lipoprotein), high level of triglycerides
- tobacco smoking
- lack of physical activity
- a low-fibre, rich in fat, high-calorie, low in calcium diet
- alcohol abuse
- history of colorectal cancer in the family (especially first-degree relatives)

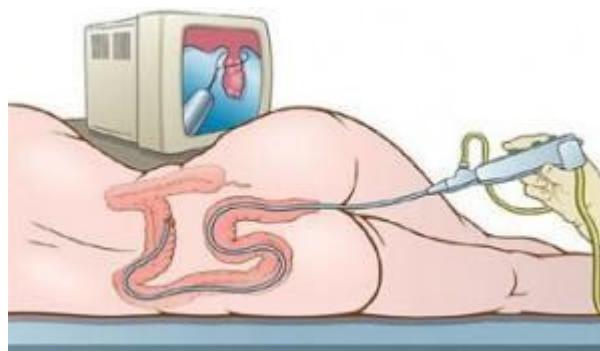
It is a known truism that "prevention is better than cure". Colorectal cancer develops for years, not minutes or days. It is, therefore, all the more important to look into our everyday habits to minimise the future risk of developing this serious condition. We should eat vegetables and fruit because they contain natural antioxidants. For the same reason, we should eliminate highly processed food with additional 'taste and colour enhancers'. It is important to remember that many of these substances pose a danger to our health, and in high doses, they can have a carcinogenic effect. A diet with little fibre slows bowel movements, prolonging the cell exposition to carcinogenic substances. It is therefore so crucial to supply about 25g of fibre per day, every day. The next step should include eliminating fast-food products with high content of trans fatty acids, which, besides being carcinogens are also responsible for causing strokes, heart attacks, impotence, atherosclerosis, diabetes or asthma.

Many patients diagnosed with colorectal cancer do not notice any symptoms of illness. One of the most frequent symptoms is the presence of blood in stool and symptoms of related anaemia from iron insufficiency (e.g. tiredness, weakness). In about $\frac{3}{4}$ of patients, bleeding is occult, which means that in their case faecal occult blood test may be useful as a screening method. Other symptoms include: change in bowel movements, weight loss, palpable mass in the abdominal area, bloating, lack of appetite. There are several cases of patients admitted to the hospital with intestinal obstruction caused by colorectal cancer which blocks the passage. Such manifestation is a sign of an advanced stage of cancer, at least locally.

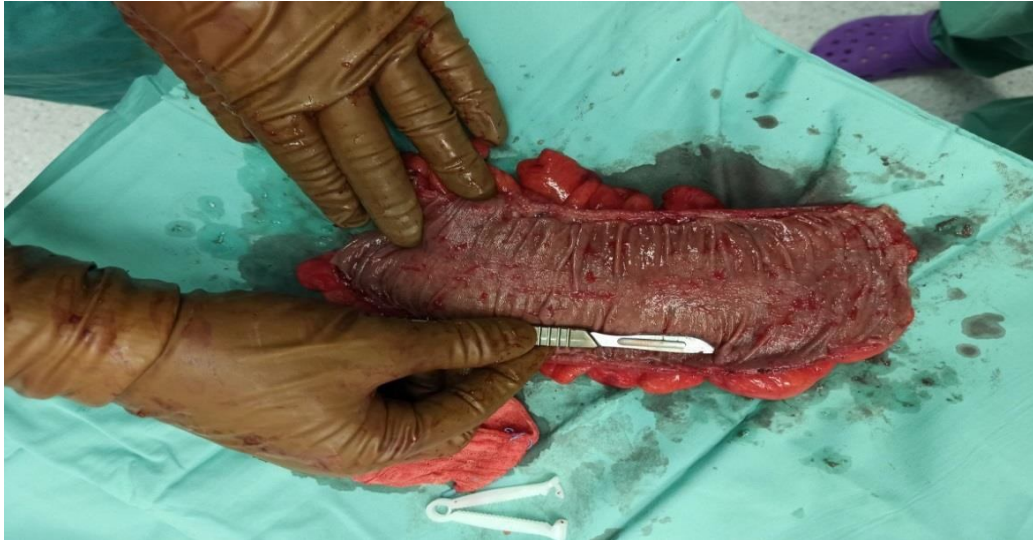

Considering that, if you belong to the high-risk group of colorectal cancer and you notice any concerning symptoms, you should contact your primary care physician to begin the diagnostic process.

In the endoscopic laboratory of Józef Psarski Mazovian Specialist Hospital in Ostrołęka, we perform a colonoscopic examination as a part of a screening programme for colorectal cancer detection. It is as important, because colonoscopy allows diagnosing colorectal cancer, but also, in cases of early-stage cancer (cancer in the polyp) during endoscopy, polypectomy (excision of the cancerous polyp) can be performed, reaching the therapeutic purpose.

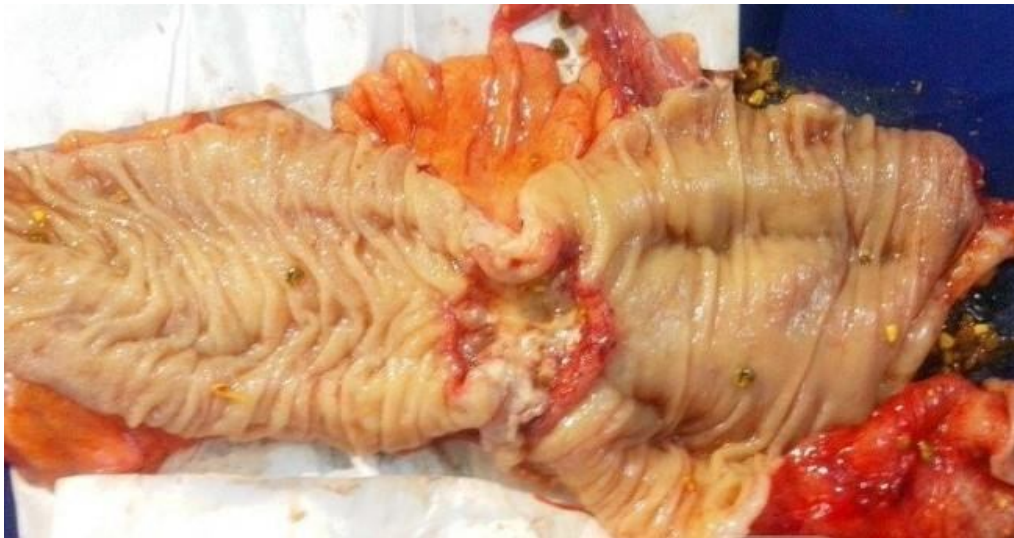

In the General Surgery Department named after dr Jerzy Olszewski with the Subdepartment of Oncological Surgery in the dr Józef Psarski Mazovian Specialist Hospital in Ostrołęka the team of surgeons performs radical and palliative surgeries in the field of colorectal cancer, using modern surgical techniques, both with laparoscopic and open methods. The team of experienced oncological surgeons guarantees the highest level of surgeries, according to the guidelines of Polish and World Oncological and Colorectal Surgery Associations.



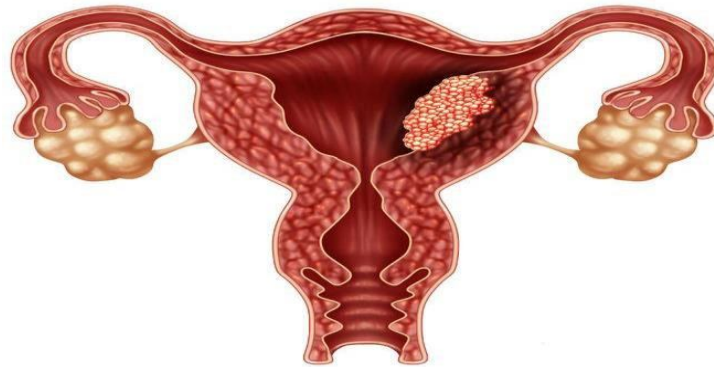State after non-radical colonoscopic polypectomy- the knife ending indicates the location of colon cancer infiltration in the sigmoid colon.

After reaching the diagnosis of colorectal cancer, imaging such as CT or MRI should be made as well as laboratory tests, to specify the stage of cancer and allow for qualification to adequate treatment.



Sigmoid cancer- local stage T3

ENDOMETRIAL CANCER



According to world statistics, endometrial cancer is the second most prevalent female genital cancer. If we consider incidence rates of malignant cancers depending on a geographical location, in the developed countries, endometrial cancer prevails over cervical cancer, reaching 4th place, right after breast cancer, lung cancer and colon cancer. The highest incidence of endometrial cancer is noted in North America.

In Poland, according to the data from the National Cancer Registry, malignant tumours of endometrium account for 7% of cancers.

The peak incidence of endometrial cancer falls within the perimenopause, between the ages 55 and 64. From the age of 65 to 70, the risk of developing endometrial cancer is systematically decreasing.



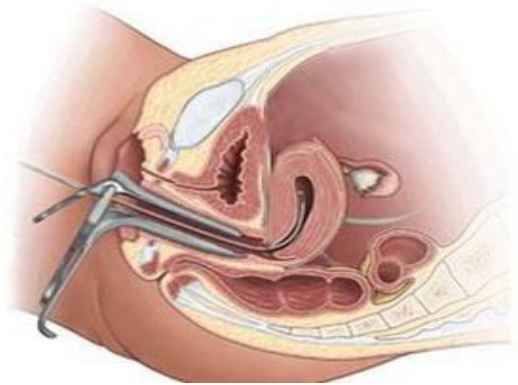
Endometrial cancer is the most prevalent malignant tumour in women in the developed countries. It is explained with a common occurrence of obesity, hypertension, type 2 diabetes, sedentary lifestyle and low birth rate. It is claimed that factors such as metabolic syndrome, lack of physical activities, advanced age, early menarche, late menopause, no offspring and menstrual disorders predispose women to endometrial cancer. Among the other risk factors for this type of cancer,

it is worth to mention hormone replacement therapy and tamoxifen. There are also genetic predispositions to endometrial cancer, such as hereditary non-polyposis colorectal cancer (Lynch syndrome) and rarely- Cowden syndrome. Type II endometrial cancer is most often revealing itself among women with low body weight in their 70s or 80s. Type I cancers are diagnosed early in 75-80% of cases, they are characterised by slow progression and good prognosis. The dominant histological type develops from endometrial hyperplasia with atypia as a result of excessive oestrogen stimulation.



Effective fight with obesity and metabolic disease is undoubtedly a factor that decreases the risk of developing endometrial cancer. It includes keeping a healthy body weight measured by BMI (body mass index) within the norm of 18,5-24,99. Optimal body weight is maintained thanks to a well-balanced diet, which restricts meat intake, replacing it with vegetables and fruit. According to studies, excessive meat consumption is a cause of many cancers, mainly colorectal cancer and endometrial cancer in women. It is not always easy to keep the right body weight. For patients suffering from morbid obesity, it is practically impossible without surgical assistance. Bariatric procedures such as gastric or intestinal reduction come to the rescue. Another important protective factor is physical exercise. Numerous scientific data confirm that lack of physical activity is associated with a higher risk of cancer, including endometrial cancer. Studies have shown that the risk of endometrial cancer may decrease by 20-30% with physical exercise. During moderate physical exercise, activation of immunological mechanisms appears. Increased activity of granulocytes and lymphocytes promotes cancerous cells destruction. It is a proven fact that oral contraception use decreases the risk of endometrial cancer, but it only applies to combined oral contraceptive (oestrogen-progestogen) pills. Multiple pregnancies reduce the risk of developing endometrial cancer. Every pregnancy shortens the time of exposition to oestrogens and prolongs a high progesterone concentration. These hormonal changes result in protection against endometrial cancer. There are several causes of cancer incidence connected to lifestyle. The best protection from cancer is a combination of a healthy diet, regular movement, a sufficient amount of rest and joy of life.

Unfortunately, there are no screening tests for endometrial cancer equivalent to cytology for cervical cancer or mammography for breast cancer. Gynaecologists alarm to report to them after noticing concerning symptoms because only timely diagnosis and early treatment enable capture of endometrial cancer in the early stages, which substantially increases the chance of recovery. Specific tests are recommended for women at high risk of developing this cancer, such as patients suffering from Lynch syndrome, PCOS, obesity, hypertension, patients with a positive family history of breast, endometrial or colorectal cancer. These women pay attention to having regular gynaecological visits with transvaginal ultrasounds.

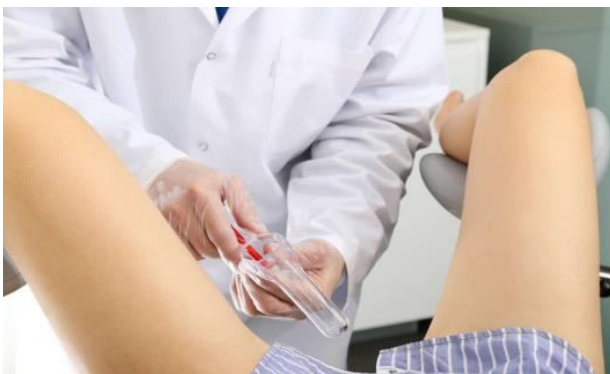
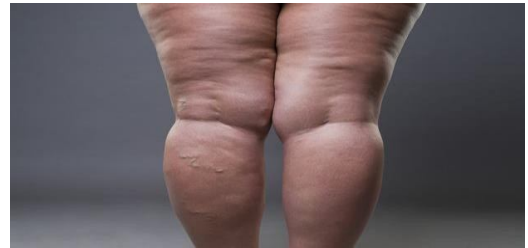
According to guidelines, all women should do regular gynaecological control visits for endometrial cancer prevention and early detection of suspicious changes in the endometrium.

Despite the histological diversity of endometrial cancers, the most common and often the only symptom is abnormal uterine bleeding, caused by the destruction of cancerous tissues. The frequency of bleeding in patients with endometrial cancer is estimated to be about 90%. The bleeding prompts women to further investigate the cause, which is why endometrial cancers are diagnosed in 75% of cases at the first, early stage of the disease. It is estimated that 20% of postmenopausal bleeding is associated with endometrial cancer.

With time from menopause, the probability of a cancerous origin of bleeding is rising.

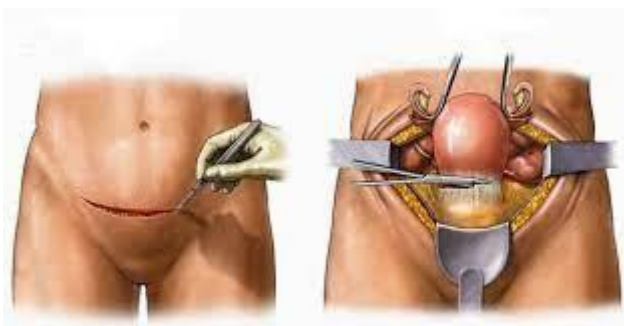Other symptoms of endometrial cancer include bloody purulent discharge, lower abdominal and sacral pain and oedema of lower extremities. The symptoms are associated with the infiltration of surrounding tissues and organs, mainly the urinary bladder, rectum, blood and lymphatic vessels and nerves. The late symptoms include anaemia and weight loss. About 5% of endometrial cancers are asymptomatic. They are diagnosed based on the abnormal view of endometrium in transvaginal ultrasonography.



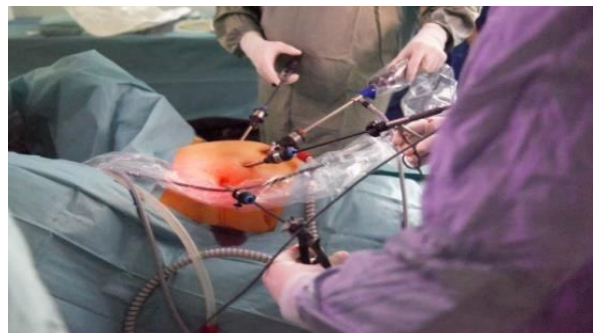Currently, the search for screening methods for endometrial cancer is ongoing. Regular gynaecologic controls in the peri- and postmenopausal period, remain an essential component in preventive management. In the case of suspected endometrial cancer, diagnostic imaging and pathomorphological diagnostic methods are utilised.

The operative treatment plays an essential role in the therapeutic process of patients suffering from endometrial cancer.

Total hysterectomy with bilateral salpingo-oophorectomy (adnexectomy) is a main surgical procedure performed due to endometrial cancer.



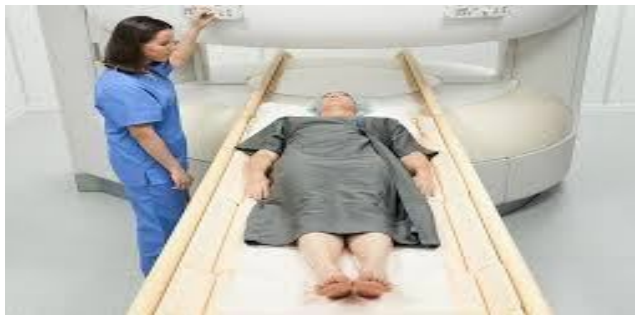In the last two decades, it is becoming more common to perform this procedure laparoscopically.



After opening the abdomen it is recommended to collect peritoneal fluid or peritoneal washings for cytological examination. Afterwards, a thorough inspection of the abdominal cavity is performed, including the parietal peritoneum, the liver, the omentum, the intestines, and also pelvic and periaortic lymph nodes. Moreover, the extent of surgery for endometrial cancer involves the excision of the adnexa.

The relevant distinctions in the surgical treatment of endometrial cancer include the situations in which the preoperative diagnosis indicates different than the endometrial histological type of cancer. Serous, papillary, and clear-cell carcinomas result in a more aggressive clinical course and a significantly worse prognosis. For these patients, a surgical protocol for ovarian cancer is applied.

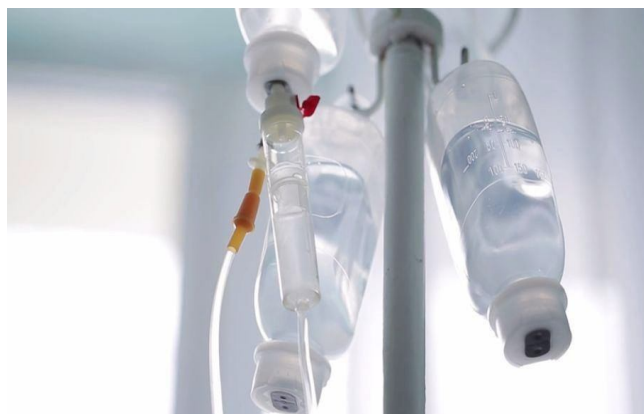A relevant subject connected with endometrial cancer surgery is a surgical treatment for carcinomas in higher than I FIGO stage. In the majority of clinical situations, II stage cancer is diagnosed in the postoperative sample. In the case of the II FIGO stage before surgery, the patient should undergo an extended hysterectomy with adnexectomy and para-aortic and pelvic lymph node excision. The risk of metastatic disease in this stage is assessed at 30%.



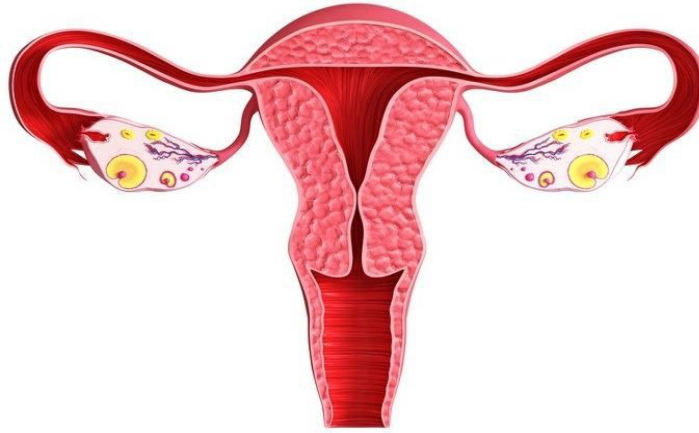
Some patients, especially those with internist contraindications to surgery such as pathological obesity, uncontrolled diabetes, can be treated radically with radiotherapy.

Also, patients with recurring endometrial cancer can be treated successfully with radiotherapy. It enables to decrease the number of local recurrences, but as studies show, it does not explicitly cause the decrease in the incidence of metastases or total survival.

Chemotherapy in the early stages (FIGO I and II) is recommended in case of coexisting risk factors for recurrence, such as high-grade of malignancy, deep infiltration of endometrial muscle, occupying space around the lymphatic vessels, tumour diameter of more than 2 cm. In type II carcinomas, it is recommended to apply adjuvant chemotherapy regardless of the tumour stage.



OVARIAN CANCER



The incidence of malignant cancers of the ovaries is 5%, 80% of ovarian cancer cases appear after the age of 50. The risk of developing ovarian cancer is increasing with age until the seventies, afterwards, it decreases. The 5-year survival rates are mostly determined by the clinical grade of the disease, histological type and histological maturity, patient age and the extent of the surgery and they decrease with the advancement of the disease. 5-year survival rate in the I grade amount between 78% and 92%, in the II grade- 70%, in the III- 37% and in the IV- from 14-25%. It is estimated that 5-15% of ovarian cancer cases are associated with carrier state of mutated genes BRCA1/2 and MMR, responsible for developing Lynch syndrome. The clinical and histological heterogeneity of ovarian cancer has a molecular foundation. In 2004 Shih and Kurman, have proposed a dualistic model of ovarian cancer carcinogenesis.

According to the proposed theory, ovarian cancer can be divided into two types:

Type I - which contains cancers with low malignancy potential (low grade). These cancers are characterised by slow growth and a good prognosis: the 5-year survival rate is approximately 55%,
Type II - which includes poorly differentiated, high-grade tumours.

The peak incidence of ovarian cancer in the world is at the age of 65. Hereditary cancers develop approximately 10 years before sporadic cancers. The age of menarche does not impact late ovarian cancer development.

Factors which favour ovarian cancer development:

- infertility,
- nulliparous women.

Factors which decrease the risk of ovarian cancer:

- oral hormonal contraception use largely decreases the risk of ovarian cancer. Two hypotheses have been introduced regarding the connection between OC use and ovarian cancer. The first hypothesis assumes that this medication reduces the risk of

cancer by preventing the ovarian epithelium from bursting during ovulation and the second one suggests that hormonal changes during pregnancy, especially high levels of progesterone, lead to the elimination of the transformed epithelial ovarian cells through apoptosis.

- prolonged lactation,
- the impact of hormone replacement therapy on ovarian cancer development has not been clearly described. It depends on the type of substance, patient age and treatment duration.
- multiparous women.

The studies show a connection between diet type and cancer development, including ovarian cancer. Information from the studies is consistent with the known healthy nutrition recommendations:

- maintain healthy body weight,
- reduce the overall fat consumption (nutrition norms recommend about 30% of whole calorific value in the diet),
- replace some of the animal proteins (meat products) with legumes, soybeans in the form of seeds, soy flour, tofu or soy milk products,
- remember about supplying beta-carotene (provitamin A) with food, e.g. carrot, pumpkin, tomato, potato, red paprika, broccoli, kale, apricot, plum, peach, mango and other fruit and vegetable.

A diet based on vegetable, fruit, a limited amount of saturated fatty acids and a balanced proportion of plant versus animal protein reduces the risk of ovarian cancer and improves the overall health status.

We should not forget about the everyday physical activity (minimum 30 minutes per day), which, as mentioned earlier, has a substantial impact on ovarian cancer risk reduction.

Despite huge efforts towards early detection of ovarian cancer, apart from complicated cases, and rare, hormonally active tumours, detection in early stages is mostly coincidental. It is a huge problem of oncological gynaecology. Ovarian cancer is currently the most frequent cause of death from genital tumours in Poland. Poor epidemiological indexes are caused by late detection and advanced stage of the disease at the time of diagnosis.

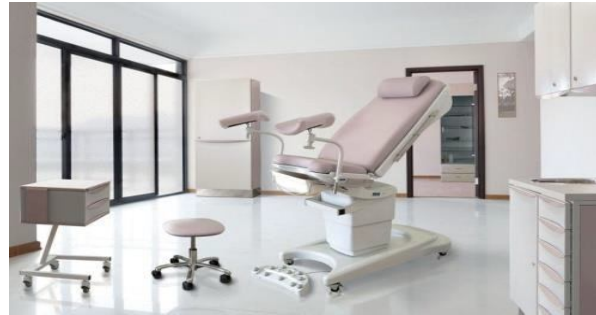Considering that, suspicion of ovarian cancer is based on family history, physical examination and complementary tests. On the one hand, the symptoms can be misleading and not very concerning to



the patients, on the other hand, they do not prompt the doctors to recommend a detailed diagnosis. The final diagnosis is achieved with a substantial delay. The symptoms may include dysuria, tension, fullness

during eating, bloating, irritable bowel syndrome symptoms. These cases should be carefully supervised and thoroughly diagnosed. Abdominal circumference increase, resulting from ascites, dyspnoea and weakness that stem from a fluid collection in the pleura, abnormal uterine bleeding, nerve pain connected with infiltration on the lesser pelvis plexuses, lack of appetite, vomiting, loss of weight, jaundice and cachexia determine the III or IV FIGO stage.

Besides the late patient check-in, other factors that delay the diagnosis during the first visit are lack of gynaecological examination, diversity of symptoms, depression, stress, IBS, dyspepsia, young age. The women with a family history of breast or ovarian cancer, carriers of BRCA1/2 genes should be also taken into account and covered with annual control visits, ultrasonography and biomarker monitoring, including Ca125.

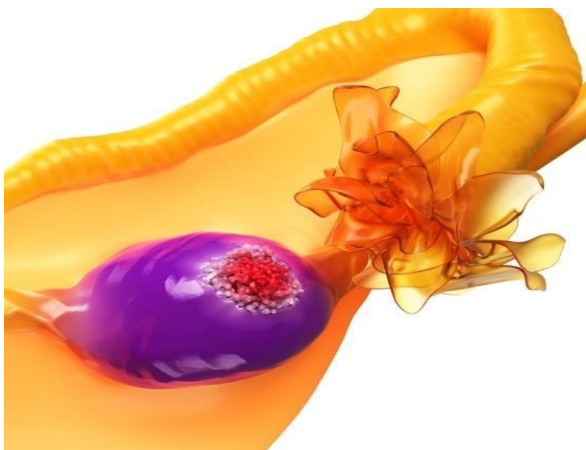

The I stage of the ovarian, fallopian tube and peritoneal cancer

The first stage of cancer is described when the ovary or Fallopian tube is occupied by cancer or the presence of neoplastic cells in fluid or peritoneal washings is confirmed.

II stage cancer of the ovary, salpinx and peritoneum

The II stage which includes about 10% of all ovarian cancers remains challenging to define and quite heterogeneous. It applies to situations when the ovarian tumour is directly infiltrating other structures in the lesser pelvis, and cases with metastases to the peritoneum of the lesser pelvis (below the planum aditus of the pelvis). The sigmoid colon and the rectum are located in the pelvic cavity, so the metastases and infiltration of these organs (without the infiltration of muscles and mucous membrane) should be classified as the II stage.



Stage III of the ovarian, fallopian tube and peritoneal cancer

The III stage comprises most cases of ovarian cancer. It includes the patients with metastases outside of the lesser pelvis area; to the peritoneum, diaphragm, omentum, intestines, liver capsule, splenic capsule, without involving the parenchyma of these organs, finally the intraperitoneal lymph nodes. As far as the frequency of lymph node metastasis in the I and II stages of cancer is 9% and 36% relatively, in the III stage, it reaches 55%. There are descriptions of isolated metastases to para-aortic lymph nodes.

IV stage ovarian, fallopian tube and peritoneal cancer

The IV stage of cancer includes distant metastases, excluding the peritoneal changes (stage II or III)

Treatment

The foundation of ovarian cancer treatment is a combined therapy, which includes surgery and chemotherapy.



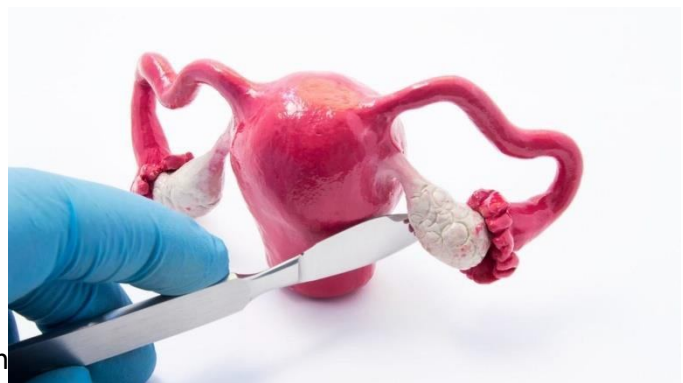Surgical treatment

The extent of surgery and adjuvant therapy depends mainly on the clinical grade.

Cancer that is confined macroscopically to the reproductive organ

After the abdominal cavity inspection, having excluded the presence of macroscopic changes outside of the pelvis, the surgical treatment includes:

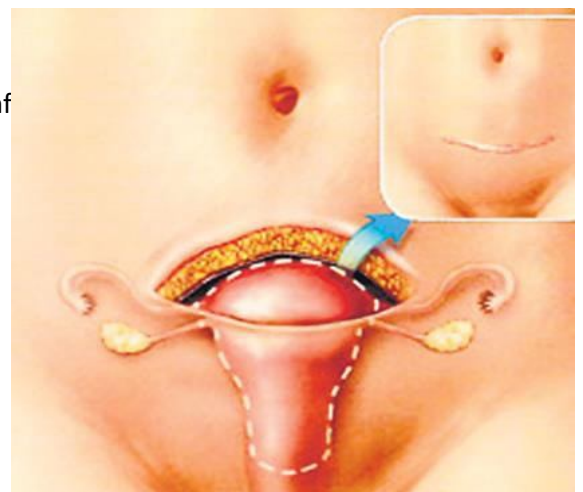
- collection of peritoneal fluid and washings for cytology (before commencing the surgical procedures);
- bilateral adnexal excision;
- total hysterectomy
- omentectomy;
- smear sampling and random collection of samples from the peritoneum
- performing a pelvic and aortic lymphadenectomy
- appendectomy is only recommended in case of macroscopic changes involving the appendix



In young women, to preserve fertility, in case of a tumour, confined capsule infiltration and intraperitoneal adhesions with G1 or G2 histological grade, the uterus and the second ovary can be preserved.

Advanced ovarian cancer

The primary aim of the surgery is total cytoreduction- lack of macroscopic residual disease.



The aim of the procedure is the excision of all visible cancerous changes. In case of inability to reach this goal, optimal cytoreduction should be accomplished (residues of <1 cm in diameter).

It is crucial to identify the patients who do not have a chance to reach at least the optimal cytoreduction because of the advanced disease. The main reason limiting the patients from the total cytoreduction in the III stage are tumours in the mesentery and the hepatic hilum. Non-resectable focal points of more than 1cm in the thorax should be treated similarly.

During qualification for surgery, the imaging studies such as CT or MRI should allow for the exclusion of left residues of >1 cm in diameter. Multiple data suggest that using Fagotti criteria (laparoscopic re-election assessment) could be an effective method for patient selection. In the case of laparotomy with an inability to reach optimal cytoreduction, the aim is to restrict the extent of surgery to reduce the possible postoperative complications and refer the patient to chemotherapy.

During qualification for surgery or during the resectability assessment (laparoscopic or with laparotomy), the patients without possibility to obtain at least optimal cytoreduction, are the candidates for neoadjuvant chemotherapy.

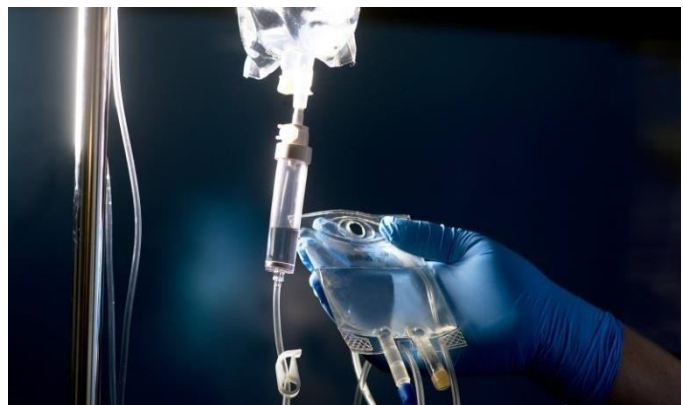Non-optimal surgery shortens the time to progression and the total survival time in a significant way, which is why, the reason for not reaching total or optimal cytoreduction, should be thoroughly documented. Cytoreductive therapy of advanced ovarian cancer involves hysterectomy with adnexal and omental excision together with resection of organs occupied with cancer: spleen, diaphragmatic peritoneum, pelvic peritoneum. Mutilating surgeries should be avoided, such as total colectomy, which limits the future option for systemic treatment. Additionally, the cytoreductive procedures include enlarged retroperitoneal lymph nodes excision.

Chemotherapy

The majority of patients with ovarian cancer have indications for systemic treatment. Withdrawal from adjuvant chemotherapy is possible only in a limited group of patients.

In the remaining patients in the I stage, the basis of treatment is a combination of platinum derivatives (carboplatin or cisplatin) and taxoid (paclitaxel), administered intravenously in the 21 day regimen.

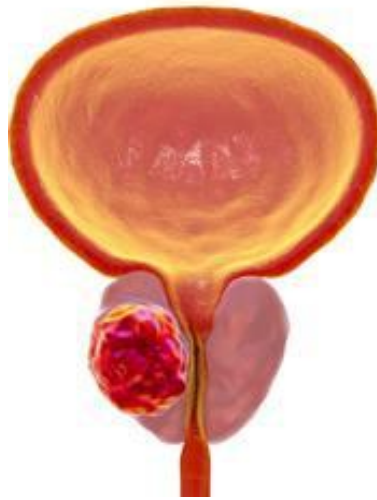The treatment should consist of 3 or 6 cycles.



Both chemotherapy treatment regimens have an identical efficacy. Better tolerance and comfort of intake speak for carboplatin. In patients with higher stages of the disease (IIB-IV FIGO) post-operative chemotherapy involves routinely 6 cycles.

Performing a CT scan before qualification for chemotherapy should be a standard procedure. It enables an objective assessment of the treatment results and qualification for bevacizumab use.

PROSTATIC CANCER



The prostate is a part of the male reproductive system. It is located below the urinary bladder, with the urethra passing through the prostatic parenchyma. Prostatic cancer is one of the most prevalent malignant cancers in men. It is estimated that half of the men aged between 60 and 70, suffer from prostatic cancer. The incidence of prostatic cancer is constantly rising. It is however worth to mention, that in many men with prostatic cancer, the illness never manifests itself clinically and does not necessitate treatment. Prostatic cancer is most often found in the peripheral part of the gland. This location enables detection of pathology during rectal physical examination. Prostatic cancer becomes symptomatic in relatively late stages of the disease. In the early stages, it mostly remains asymptomatic. Cancerous cells circulate in the blood and may create distant metastases. Most often they travel to lymph nodes, bones, and lungs. In some patients metastatic disease forms relatively early, in others, we observe the locally limited character of the neoplasm with metastases forming late in the course of the disease.

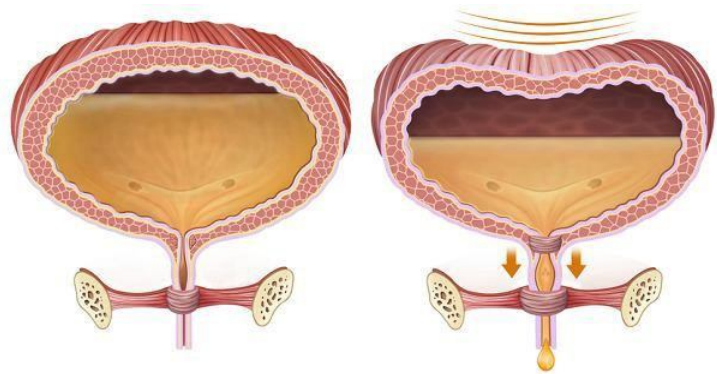
Risk factors favourable for the development of prostatic cancer include:

- age,
- family history of prostatic cancer,
- race (Afro-American).

Early detection of cancer increases the chance of recovery. Suspicion of prostatic cancer drawn from physical examination or abnormal concentration of PSA in the blood are the first steps towards diagnosis. Most men do not experience any symptoms whatsoever. Some may experience slight dysuria, which intensifies throughout the years and is often underestimated by patients. Meanwhile, the onset of clinical symptoms is often a sign of advanced-stage neoplastic disease (the tumour has grown so much that it obstructs urine outflow from the bladder or infiltrates the surrounding tissues).

Symptoms of abnormal voiding function include:

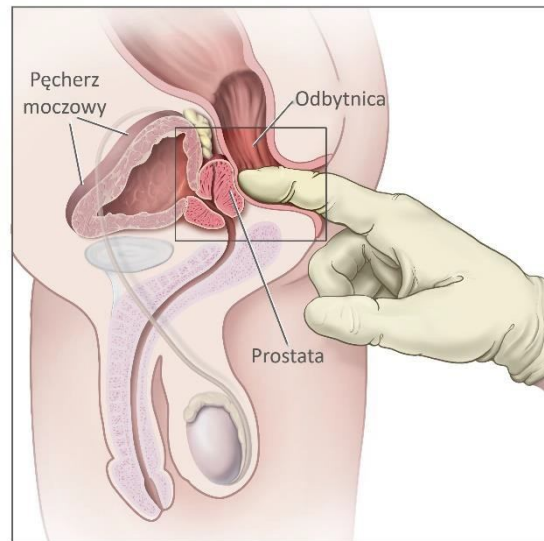
- frequent urination, also occurring multiple times at night (nocturia)
- difficulty starting urination
- difficulty maintaining a steady stream of urine (weak or intermittent urine outflow)
- urine retention (feeling of incomplete emptying of the bladder)
- strong, urgent need for urination (urgency)



In the case of men with advanced prostatic cancer first symptoms may include back pain, hip pain, pelvic pain- these can mean that cancer has already metastasized to bones.

The first step in diagnosing prostatic cancer, besides medical history, is the digital rectal examination (DRE). During the examination, the patient is positioned in either a standing position (prone jack-knife), knee-chest position, or right lateral decubitus position. During the examination, the patient might experience slight discomfort.

PSA is a commonly used specific biomarker for prostatic disease. The abnormal result of the PSA test might be a result of prostatic cancer, but also other prostatic abnormalities. A high PSA level is not equivalent to a prostatic cancer diagnosis. The most common reasons for the abnormally high level of PSA in the blood include benign prostatic hyperplasia and local inflammation. The definite diagnosis of prostatic cancer is based on biopsy, which involves sampling the tissue with a special needle.



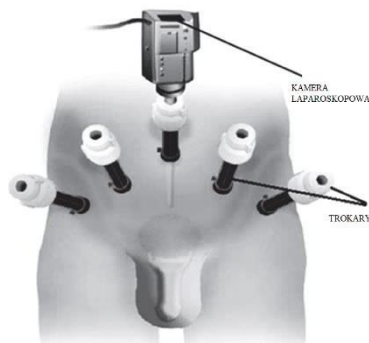
Biopsies are ultrasound-guided. The ultrasound probe is introduced inside the rectum. The collected prostatic tissue samples are assessed under the microscope. The diagnostic tools for prostatic cancer stage assessment include MRI, CT, and bone scintigraphy.

There are several commonly available methods of treatment. Among these, the most important are:

- active surveillance
- surgical treatment (radical prostatectomy)
- radiotherapy
- hormonal therapy
- chemotherapy.

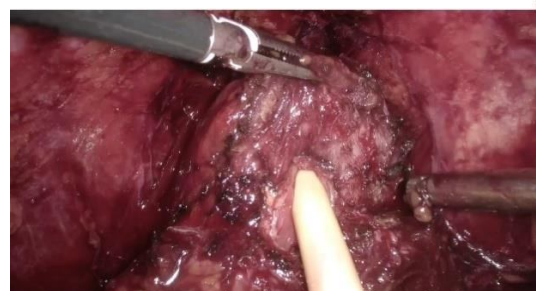Active surveillance is about constant monitoring of the disease status to introduce radical treatment immediately in case of progression. The surgery consists of removing the cancer tissue with the total excision of the prostatic gland together with the seminal vesicles and distal parts of the vas deferens. Radical prostatectomy is performed with the classic open method, laparoscopically or laparoscopically with robotic assistance. The procedure is performed under general anaesthesia.

In the case of open surgery, the urologist opens the abdominal cavity, making a vertical incision from the umbilicus to pubic symphysis. During the procedure the cancerously changed prostatic tissue is diligently removed together with the surrounding tissues and sometimes even with pelvic lymph nodes. All the excised structures are sent to histopathological examination, which establishes the level of malignancy and stage of cancer. The surgery is completed with the reconstruction of the connection between the urethra and the urinary bladder. During the surgery, the catheter is placed inside the bladder, introduced before surgery through the urethra.

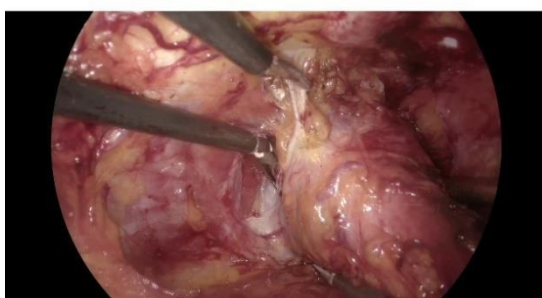

The first step in laparoscopic prostatectomy is making a small incision in the skin around the umbilicus. Through this incision, the gas is pumped inside the abdominal cavity. Subsequently, through consecutive skin incisions, a laparoscopic device is introduced inside the abdomen.

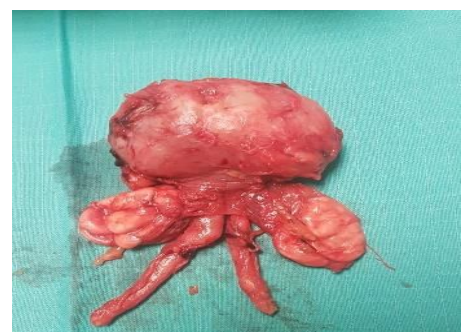The camera transmits the image, visible on the monitor. The successive stages of surgery are



equivalent to the open surgery method.



Among the advantages of laparoscopic surgery, one shall mention a shorter hospital stay, faster recovery to normal physical activities,



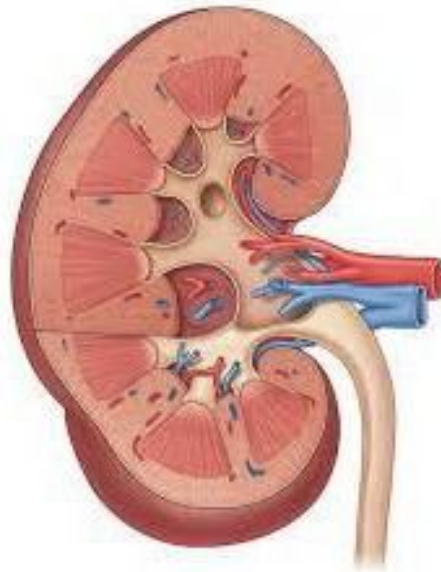
attributed to smaller intraoperative tissue destruction, smaller risk of infection, and better final cosmetic effect.

Radiotherapy is a method that uses radiation to destroy cancerous cells. There are two main types of radiotherapy: external beam radiation therapy and brachytherapy.

Hormonal treatment for prostatic cancer most often involves decreasing the concentration of testosterone in the bloodstream. This type of treatment is meant to result in slowing of cancer progression or even tumour size reduction. Sometimes despite reaching initial control over the disease, the patient, unfortunately, experiences relapse (recurrence) of cancer. In the last years, there has been a significant improvement in treating advanced stages of prostatic cancer.

Regardless of the treatment method, the patient requires insightful observation and regular urological control visits.

KIDNEY CANCER



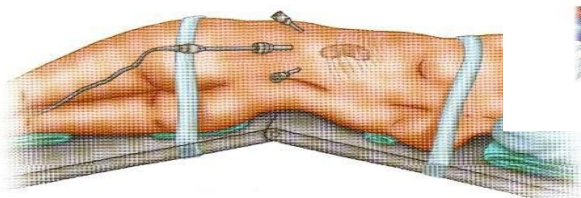
Kidney tumours are often incidentally discovered during an abdominal ultrasound. Kidney tumours can be divided into benign and malignant. Benign tumours are characterised by slow local growth and lack of metastases. Some of them require surgical excision because of large growth, which threatens tumour rupture or sudden bleeding. Kidney cancer is a malignant tumour, which initially grows slowly but steadily, and may finally result in metastatic disease. In the beginning renal cancer is asymptomatic, symptoms such as pain or haematuria are revealed in the late, advanced stage of the disease. Most patients suffering from renal cancer are over 50 years old. It is more prevalent in men than in women and it is rarely hereditary.

Factors that increase the risk of being affected by renal cancer are:

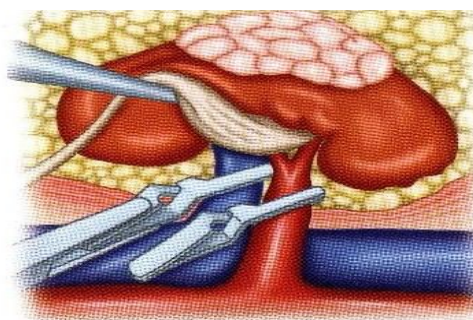
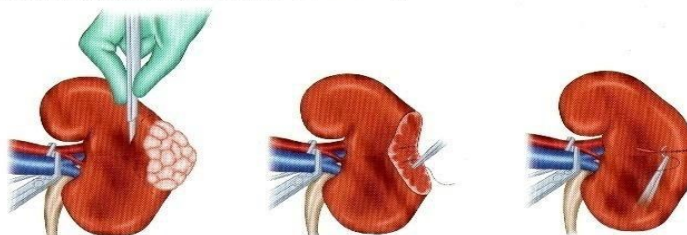
- environmental pollution,
- tobacco smoking,
- obesity.

After an incidental finding of renal mass on the ultrasound, several complementary tests need to be performed. Besides the routine blood and urine tests, a chest X-ray should be carried out, as well as a CT scan or abdominal MRI. It is uncommon to perform renal tumour biopsy. The definite diagnosis of renal carcinoma is confirmed in the histopathological exam of the excised specimen.

The fundamental treatment method for



Nefrektomia częściowa metodą otwartą



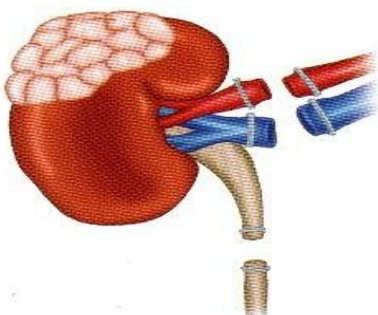
renal carcinoma is surgical management. Surgical treatment involves removal of renal tumour (so-called partial nephrectomy) or in case of larger tumours, total nephrectomy. The abovementioned procedures can be performed with the classical open method or laparoscopically.

Open radical nephrectomy is made by a 10 cm incision along the abdomen just below the ribs. In the case of laparoscopic nephrectomy, there are three or four small 1,5 cm incisions. The decision about the type of surgery depends on several factors such as size, location of the tumour, patient general condition and other comorbidities.

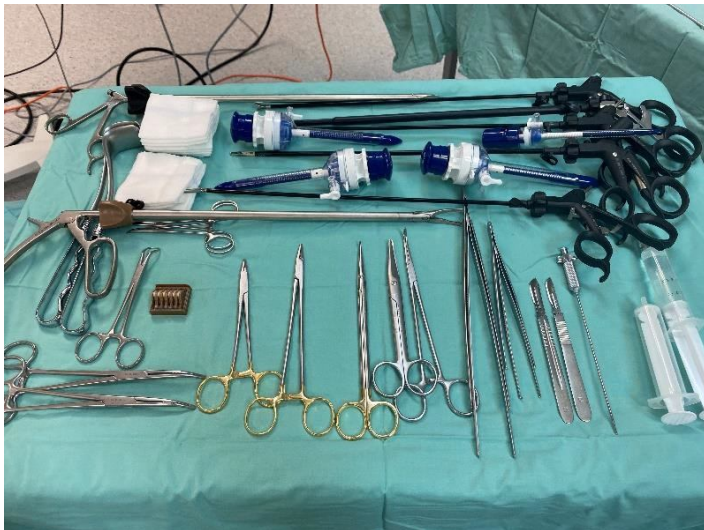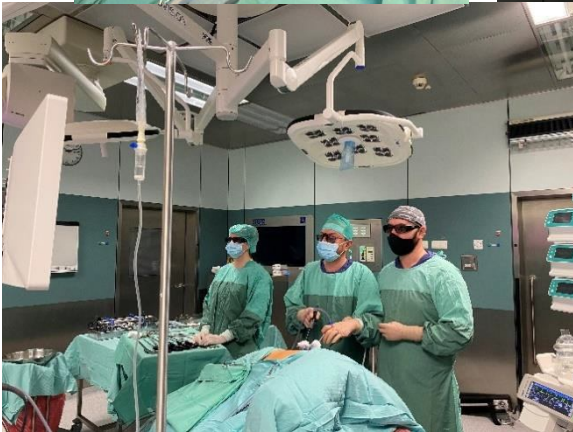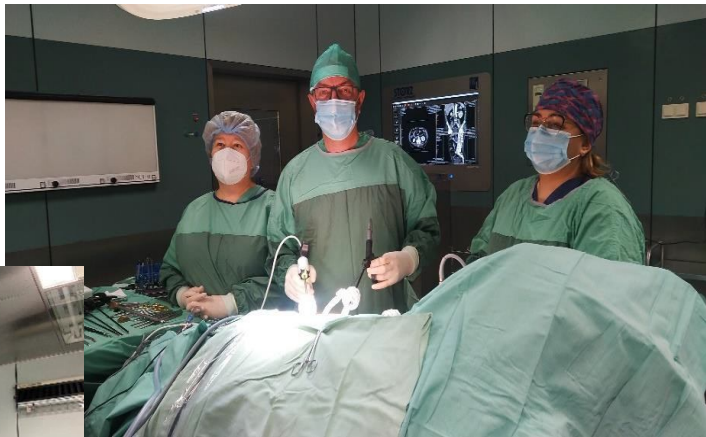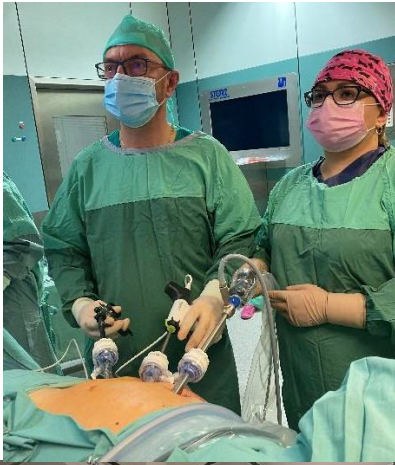Patients that have undergone laparoscopic procedures do not require huge amounts of pain medication and their recovery time is shorter.

Partial nephrectomy is a standard procedure for tumours less than 4 cm in diameter. During this surgery,

Nefrektomia radykalna



the renal tumour is excised with a margin of healthy tissue, to spare as much of the healthy renal tissue as possible. Partial nephrectomy is often described as a nephron-sparing surgery (NSS).



Since most renal tumours develop gradually, they do not pose an actual life threat to some patients with several comorbidities or in advanced age. In such patients, the preferred management method is active observation. Treating advanced, diffuse renal carcinoma requires a multidisciplinary approach. Several specialists, among them urologists, oncologists, and radiotherapists take part in this process.

Remember, an early diagnosis increases chance of recovery!

References:

1. "An Atlas of Surgical Anatomy" by Alain C Masquelet; 2005, Taylor @ Francis
2. "Fundamentals of Pediatric Surgery", Peter Mattei ; Springer, 2011.
3. "Хирургические болезни детского возраста", 2 том. Ю. Ш. Исаков; 2011, Москва
4. "Pediatric surgery and urology. Long-term outcomes" second edition; Mark D. Stringer; 2006, Cambridge University Press.
5. FedirYurochko, Wojciech Domka, Dzvenyslava Kopanska. Otitis Media. Inflammation or Infection? 4(5). Research in Pediatrics & Neonatology. 000598. 2020. DOI: 10.31031/RPN.2020.04.000598
6. Косаковський А.Л., Юрочко Ф.Б., Копанська Д.Б. «Середній отит. Атлас» видавництво МС (Львів), 76 сторінок 2020
7. Юрочко Ф., Косаковський А., Шкорботун В. «Дитяча Ринологія», книга, видавництво МС (Львів), 268 сторінок, 2020
8. Юрочко Ф., Копанська Д. Сучасне хірургічне і медикаментозне лікування хвороб аденоїдів Оториноларингологія, №2 (1), 2018, 87-93 сс.
9. Юрочко Ф. Лікування гіпертрофії аденоїдів. Балансуючи між аденотомом і ліками. СЕМЕЙНАЯ МЕДИЦИНА №3 (77)/2018, стор. 100-106
10. Книга «Дитяча отологія» за редакції А.Косаковського та Ф.Юрочка, видавництво Мс, Львів 288 стор. 2017
11. S. Tekgul, H. Riedmiller, E. Gerharz, P. Hobeke, R. Kocvara, R. Nijman, Chr. Radmayr, R. Stein "Pediatric urology", ESPU, 2011
12. Alan J. Wein, Louis R. Kavoussi, Andrew C. Novick, Alan W. Partin, Craig A. Peters, W. Scott McDougal, and Parvati Ramchandani "Campbell-Walsh Urology: Pediatric Urology" 11th edition, Elsevier - Health Sciences Division, 2014
13. Varga J, Zivkovic D, Grebeldinger S, Somer D. "Acute scrotal pain in children—ten years' experience". Urology 2007
14. Cavusoglu YH, Karaman A, Karaman I, Erdogan D, Aslan MK, Varlikli O, Cakmak O. "Acute scrotum – etiology and management", Indian J Pediatr, 2005
15. Okuyama A, Nakamura M, Namiki M, Takeyama M, Utsunomiya M, Fujioka H, Itatani H, Matsuda M, Matsumoto K, Sdonoda T. "Surgical repair of varicocele at puberty: preventive treatment for fertility improvement", J Urol, 1998
16. Riccabona M, Oswald J, Koen M, Lusuardi L, Radmayr C, Bartsch G. "Optimizing the operative treatment of boys with varicocele: sequential comparison of 4 techniques", J Urol 2003
17. Barthold JS, Kass EJ. "Abnormalities of the penis and scrotum". In: Belman AB, King LR, Kramer SA (eds). Clinical pediatric urology. 4th edn. London: MartinDunitz, 2002, p 1093-1124
18. Pyoralá S, Huttunen NP, Uhari M. A review and meta-analysis of hormonal treatment of cryptorchidism, J ClinEndocrinol, 1995
19. Docimo SG. "The results of surgical therapy for cryptorchidism: a literature review and danalysis", J Urol, 1995
20. Francesco Turrà, Maria Escolino, Alessandra Farina, Alessandro Settimi, Ciro Esposito, and François Varlet "Pyeloplasty techniques using minimally invasive surgery (MIS) in pediatric patients", US NLM, Transl Pediatr. 2016 Oct; 5(4): 251–255
21. Wszystkie zdjęcia pochodzą wyłącznie z archiwum kliniki lub zostały wykonane w klinice.
22. Podstawy Chirurgii tom 1 i 2 – podręcznik dla specjalizujących się w chirurgii ogólnej, praca zbiorowa pod redakcją Jacka Szmida i Jarosława Kuźdżała, wyd. II, Kraków 2010
23. Sabiston Chirurgia, praca zbiorowa pod redakcją Cortney M. Townsend, redakcja wydania polskiego Tadeusz Popiela, Wrocław 2010
24. Chirurgia Onkologiczna, praca zbiorowa pod redakcją Arkadiusz Jeziorski, wyd I, Warszawa 2018
25. Zalecenia Polskiego Towarzystwa Chirurgii Onkologicznej
26. Normy żywienia dla populacji Polski 2017r. – opracowane przez Instytut Żywności i Żywienia im prof. dra med. Aleksandra Szczygła
27. Krajowy Rejestr Nowotworów www.onkologia.org.pl
28. Zarys ginekologii onkologicznej tom 1-2, pod red. J. Markowska, R. Mądry, Termedia Poznań 2015, wyd. 2.
29. Łukasz Wicherek, Z. Kojs, G. Bręborowicz „Ginekologia onkologiczna” wyd. PZWL, IV kwartał 2016
30. Leczenie chirurgiczne raka jajnika ESGO 2021r
31. Zalecenia Polskiego Towarzystwa Ginekologii Onkologicznej dotyczące diagnostyki i leczenia raka jajnika 2021r
32. Rak jajnika – patobiologia, diagnostyka i przegląd współczesnych metod leczenia pod red. Gabriela Wcisło i Cezarego Szczylika
33. Albers P., Heidenreich A., Podstawowe operacje urologiczne, wyd. Czelej 2017
34. Chłosta P.L., Poradnik dla pacjentów urologicznych i ich rodzin, Warszawa 2017.
35. Drewa T., Juszcak K., Urologia ilustrowany Podręcznik dla studentów i stażystów, wyd. PZWL 2018
36. EAU Guidelines. Edn. presented at the EAU Annual Congress Milan 2021
37. Partin A. W., Dmochowski R. R., Kavoussi L.R, Wein A., Peters C. A., Campbell Walsh Wein Urology, 12th Edition, wyd. Elsevier 2020
38. Reynard J., Brewster S., Biers S., Oksfordzki podręcznik urologii, wyd. Czelej 2011
39. https://pl.wikipedia.org/wiki/Badanie_per_rectum
40. <https://docplayer.pl/105078522-Laparoskopowa-prostatektomia-radykalna-lpr.html>
41. UROLOGIA ONKOLOGICZNA UKŁAD MOCZOWO-PŁCIOWY Ilustrowany materiał edukacyjny z możliwością rysowania na stronach, wyd. IPSEN